

Efficacy and Safety of Intravitreal Dexamethasone Implant in Treatment-Resistant Diabetic Macular Edema: Six-month Results

Berhuni Mustafa¹, Yılmaz İbrahim Edhem¹,
Soysal Gizem Gürbostan², Özcan Zeynep Özer², Doğan Levent³

¹Gaziantep İslam, Science and Technology University, Medical Faculty,
Department of Ophthalmology, Gaziantep, Turkey

²Gaziantep City Hospital, Gaziantep, Turkey

³Niğde Ömer Halisdemir University, Medical Faculty, Department of
Ophthalmology, Niğde, Turkey



Mustafa Berhuni, MD

Submitted to the editorial board: September 13, 2024

Accepted for publication: November 8, 2024

Available on-line: January 17, 2025

We confirm that this study is original and has not been published elsewhere nor is it currently under consideration for publication elsewhere.

There is no conflict of interest for all authors.

Correspondence address:

Batıkent mah 9005 no street 4/3

Gaziantep

Turkey

E-mail: mustafaberhuni@gmail.com

SUMMARY

Aims: To investigate the efficacy and safety of intravitreal Dexamethasone implant (DEX-I) therapy in the treatment of diabetic macular edema (DME) refractory to intravitreal bevacizumab (IVB).

Material and methods: This retrospective and cross-sectional study included 37 eyes of 37 patients who received 3 loading doses of IVB injections for DME with no response and underwent DEX-I implant. Best-corrected visual acuity (BCVA), intraocular pressure (IOP) measurements and central foveal thickness (CFT) measured by spectral domain optical coherence tomography (SD-OCT) were recorded and compared before DEX-I, at the first week, first, second, third and sixth months. Duration of DME, glycated hemoglobin (HbA1c) levels, DME types and lens status (phakic, pseudophakic) were also recorded.

Results: The mean age of the patients was 61.14 ± 8.69 years (59.5% male, 40.5% female). 35.1% of the patients had cystoid macular edema, 64.9% had diffuse macular edema and 73% were phakic and 27% were pseudophakic. BCVA, CFT and IOP values before DEX-I injection were 0.78 ± 0.16 LogMAR, 493.73 ± 107.6 μ m and 13.05 ± 2.59 mmHg, respectively. At 6 months after DEX-I, BCVA, CFT and IOP values were 0.64 ± 0.11 LogMAR, 397.35 ± 59.72 μ m and 16.3 ± 2.51 mmHg, respectively. In all follow-ups, there was a significant improvement in BCVA, a significant decrease in CFT and a significant increase in IOP compared to pre-injection. Ocular hypertension was observed in 0.8% of patients and progression of cataract progression in 1% of patients after treatment.

Conclusion: DEX-I therapy is an effective and safe treatment option for DME refractory to IVB treatment.

Key words: Dexamethasone implant, bevacizumab, diabetic macular edema, intraocular pressure, cataract

Čes. a slov. Oftal., 81, 2025, No. 3, p. 151–156

INTRODUCTION

Diabetic retinopathy (DRP) is one of the leading causes of visual loss due to diabetic macular edema (DME) [1]. In DRP, vascular endothelial growth factor (VEGF), oxidation products, monocyte chemotactic protein (MCP), interleukin-6 (IL-6), interleukin 8 (IL-8), tumor necrosis factor-alpha (TNF-alpha), which increase in the environment due to angiogenesis, oxidative stress and inflammation, inflammatory mediators such as intercellular adhesion molecule-1 (ICAM-1) cause disruption of the blood-retinal barrier, increased vascular permeability, increased extravascular fluid flow and ultimately the

development of DME in the retina and especially in the macula [2,3]. Focal and grid macular laser photocoagulation (MLP) has been used in the treatment of DME for many years [4]. Later, MLP was compared with intraocular injection therapies, such as intravitreal triamcinolone acetonide (IVTA) and it was reported that MLP combined with IVTA was more effective than MLP alone [5]. Although triamcinolone acetonide (TA) provides effective visual and anatomical improvements in DME, its short half-life, short duration of action, the need for multiple injections, and serious side effects such as glaucoma and cataracts have led researchers to search for new intravitreal (IV) agents. Studies have shown that

bevacizumab, an anti-vascular endothelial growth factor (anti-VEGF) agent approved by the Food and Drug Administration (FDA) for the treatment of colorectal cancer, provides visual and anatomical improvements in the treatment of DME [6]. Since intravitreal bevacizumab (IVB) has not yet received FDA approval for the treatment of DME and is cheaper than other anti-VEGF agents, it is used in off-label treatment worldwide. Intravitreal ranibizumab (IVR) and intravitreal aflibercept (IVA) are two anti-VEGF agents that have been shown to be effective in the treatment of DME and have received FDA approval [7,8]. Although VEGF is important in the increase of vascular permeability in the pathogenesis of DME, proinflammatory mediators are also involved [3]. Therefore, inhibition of proinflammatory mediators along with VEGF gains importance in treatment. Corticosteroids inhibit VEGF expression in retinal vessels, in addition to inhibition of proinflammatory mediators [9]. TA is the longest half-life corticosteroid with a half-life of 18.6 days and has been used in IV treatment of DME for many years, but is not preferred by most ophthalmologists today, due to its short efficacy, frequent injection requirement and serious side effects [10]. Dexamethasone (DEX) has been shown to be effective in the intravitreal treatment of DME [11]. Although DEX is a more potent steroid than TA, it is not suitable for intravitreal use, due to its 3-hour half-life. Based on this, researchers have made a revolutionary breakthrough and developed a sustained slow-release intravitreal Dexamethasone implant (Ozurdex®, Allergan, Inc., Irvine, CA, USA). The Dexamethasone implant (DEX-I) consists of a biodegradable copolymer, containing micronized 0.7 mg Dexamethasone. When implanted into the eye, it releases its total dose gradually, with sustained release over 6 months. DEX-I is FDA approved for the treatment of DME and has been shown to cause rapid reduction in macular thickness and rapid improvement in visual function in randomized controlled trials [12,13].

In our study, we aimed to investigate the efficacy and safety of intravitreal DEX-I in DME refractory to IVB treatment.

MATERIAL AND METHODS

This retrospective and cross-sectional study was conducted in the Retina Clinic of a tertiary referral hospital. The study was conducted in accordance with the principles of the Declaration of Helsinki. Ethics Committee approval was obtained from the institutional Ethics Committee and informed consent was obtained from each patient for the use of their records. One randomly selected eye of 37 patients with non-proliferative diabetic retinopathy (NPDR) and early stage proliferative diabetic retinopathy (PDR) with nuclear cataract up to grade 1, who failed to respond to 3 loading doses of IVB treatment in 3 consecutive months due to DME and were therefore treated with DEX-I (Ozurdex, Allergan, Irvine,

CA) were included in the study (one eye of patients with DME in both eyes was randomly selected). Patients who received IV injection or MLP prior to IVB loading dose, patients under 18 years of age, patients with advanced PDR, tractional retinal detachment, uncontrolled diabetes and hypertension, severe cataract, glaucoma, retinal vein occlusion (RVO), previous pars plana vitrectomy, vitreomacular traction, epiretinal membrane, retinal degenerative disease, myopia and hyperopia of 5 diopters or more, astigmatism of 3 diopters or more, age-related macular degeneration, acute, subacute and chronic uveitis, and YAG laser capsulotomy within the last 3 months were excluded. Resistant DME was defined as a decrease of less than 50 microns in central foveal thickness (CFT) measured by spectral domain optical coherence tomography (SD-OCT), or an increase in CFT 1 month after the last dose of 3 doses of 1.25 mg IVB treatment administered at one-month intervals (4 months after treatment initiation). General anamnesis of all patients was taken before the application. All blood tests, including glycated hemoglobin (HbA1c), were performed and HbA1c values were recorded.

All patients underwent visual acuity examination with Snellen's chart and best-corrected visual acuity (BCVA) was calculated and converted to LogMAR. Intraocular pressures (IOP) were measured in mmHg with Goldman applanation tonometry. Anterior segment examination was performed with slit-lamp biomicroscopy. Fundus examination was performed with a 90 diopter lens. Fundus fluorescein angiography (FFA) was performed in all patients and CFT was measured automatically with the retinal map mode of SD-OCT (Optovue RTVue XR, Optovue Inc., Fremont, CA). All patients received DEX-I (Ozurdex®, Allergan, Inc., Irvine, CA, USA) treatment. DEX-I treatment was performed under operating room conditions. Before the application, the eye area was cleaned with povidone iodine. The eye was covered with a sterile drape. Proparacaine and 10% povidone iodine were applied to the eye, followed by a 3-minute wait. Afterwards, an IV injection was administered from the upper temporal region at a distance of 4 mm from the limbus in phakics and 3.5 mm from the limbus in pseudophakics. Afterwards, the eye was closed with a sterile pad and moxifloxacin (Vigamox, Alcon Laboratories, Inc., Fort Worth, TX) drops were prescribed to be used 5 times a day for a week. BCVA, CFT and IOP of all patients were recorded before, 1 week, 1 month, 2 months, 3 months and 6 months after DEX-I administration.

Statistical Analysis

The SPSS 21.0 (Statistical Packages for Social Sciences; SPSS Inc., Chicago, Illinois, USA) program was used for statistical evaluations of the study. Compliance with normal distribution was evaluated by the Kolmogorof-Smirnov test. Measurable and parametric data were presented as arithmetic mean \pm standard deviation. Categorical variables were presented as number and percentage. The comparison of BCVA, CFT and IOP measurements over

time was performed by the repeated measures analysis of variance (ANOVA) test. The Bonferroni correction test was used for multiple comparisons. In all statistical evaluations, $p < 0.05$ was considered statistically significant.

RESULTS

The study included 37 eyes of 37 patients with DME who did not respond to 3 loading doses of IVB injection and underwent DEX-I. The mean age of the patients included in the study was 61.14 ± 8.69 years. 22 (59.5%) of the patients were male and 15 (40.5%) were female. Demographic data and medical history of the patients are shown in Table 1. Of the patients, 35.1% had cystoid macular edema, 64.9% had diffuse macular edema and 73% were phakic and 27% were pseudophakic. BCVA, CFT and IOP values before DEX-I injection were 0.78 ± 0.16 LogMAR, 493.73 ± 107.6 μ m, 13.05 ± 2.59 mmHg, respectively. BCVA values were 0.72 ± 0.17 , 0.53 ± 0.12 , 0.51 ± 0.14 , 0.51 ± 0.14 , 0.51 ± 0.14 , 0.64 ± 0.11 LogMAR at Week 1, Month 1, Month 2, Month 3 and Month 6, respectively and there was a significant improvement in all follow-ups compared to the pre-injection period ($p < 0.001$, $p < 0.001$,

$p < 0.001$, $p < 0.001$, $p < 0.001$, $p < 0.001$, $p < 0.001$, respectively).

CFT values were 450.05 ± 100.96 μ m, 342.7 ± 69.93 μ m, 339.43 ± 67.41 μ m, 340.08 ± 64.94 μ m, 397.35 ± 59.72 μ m and were significantly lower at all follow-ups than before injection ($p < 0.001$, $p < 0.001$, $p < 0.001$, $p < 0.001$, $p < 0.001$, $p < 0.001$, respectively). IOP values were 14.59 ± 1.83 mmHg, 16.73 ± 2.11 mmHg, 16.86 ± 2.62 mmHg, 17.76 ± 2.21 mmHg, 16.3 ± 2.51 mmHg and were significantly higher than before injection at all follow-ups ($p: 0.001$, $p < 0.001$, $p < 0.001$, $p < 0.001$, $p < 0.001$, $p < 0.001$, respectively). BCVA, CFT and IOP changes compared to pre-injection are shown in Table 2. BCVA, CFT and IOP changes before and after DEX-I are shown in Graphs 1,2 and 3.

Cataract progression was observed in 4 patients (1%) after DEX-I injection and 2 patients underwent phacoemulsification and intraocular lens implantation surgery. Mean IOP was 14.59 ± 1.83 mmHg before injection and 16.3 ± 2.51 mmHg 6 months after injection ($p < 0.001$). Ocular hypertension (>21 mmHg) developed in 3 patients (0.8%) and was controlled with medical treatment. Eight patients developed moderate injection-related subconjunctival hemorrhage, which resolved approximately within 15 days without treatment. Endophthalmitis, retinal detachment and other ocular complications were not observed in any patient.

DISCUSSION

Increased sorbitol and oxygen radicals in diabetes cause deterioration and hypoxia in retinal vascular structures, leading to VEGF increase and neovascularization [14]. VEGF has a very important role in the pathogenesis of DME. Recent studies have shown that inflammation is also important in DME and it has been reported that inflammation is initiated by retinal Müller cells, microglial cells and various cytokines (IL-6, IL-8, TNF-alpha etc.) and continues at a low level [15,16]. Since intravitreal administration of steroids (TA) causes complications, such as increased IOP and cataracts, and is short-acting, DEX-I, a slow-release and long-acting implant was developed [11]. DEX-I is a sustained-release, biodegradable,

Table 1. Demographic characteristics and medical history of patients

Number of patients (eyes)	37
Age (years, mean \pm SD)	61.14 ± 8.69
Gender	
Male n (%)	22 (59.5)
Female n (%)	15 (40.5)
Duration of DME (months, mean \pm SD)	30.62 ± 5.99
HbA1c (% , mean \pm SD)	7.85 ± 1.15
Type of DME	
Cystoid ME n (%)	13 (35.1)
Diffuse ME n (%)	24 (64.9)
Lens status	
Phakic n (%)	27 (73)
Pseudophakic n (%)	10 (27)

SD – Standard deviation, DME – Diabetic macular edema, HbA1c – glycosylated hemoglobin, ME – Macular edema

Table 2. Mean changes from baseline best corrected visual acuity, central foveal thickness and intraocular pressure

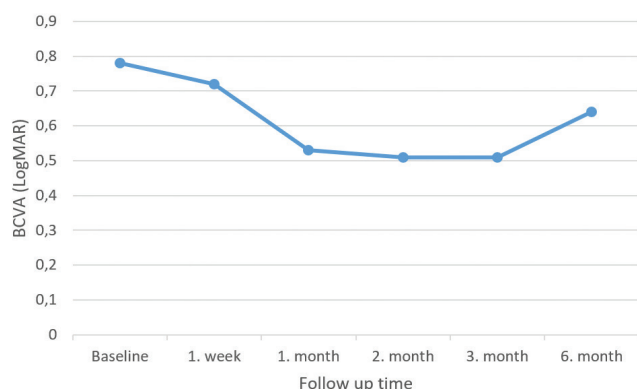
	Baseline	1. week	1. month	2. month	3. month	6. month
BCVA (LogMAR)	0.78 ± 0.16	0.72 ± 0.17	0.53 ± 0.12	0.51 ± 0.14	0.51 ± 0.14	0.64 ± 0.11
p value*	-	< 0.001	< 0.001	< 0.001	< 0.001	< 0.001
CFT (μ m)	493.73 ± 107.6	450.05 ± 100.96	342.7 ± 69.93	339.43 ± 67.41	340.08 ± 64.94	397.35 ± 59.72
p value*	-	< 0.001	< 0.001	< 0.001	< 0.001	< 0.001
IOP (mmHg)	13.05 ± 2.59	14.59 ± 1.83	16.73 ± 2.11	16.86 ± 2.62	17.76 ± 2.21	16.3 ± 2.51
p value*	-	$p: 0.001$	$p < 0.001$	$p < 0.001$	$p < 0.001$	$p < 0.001$

BCVA – Best corrected visual acuity, CFT – Central foveal thickness, IOP – Intraocular pressure

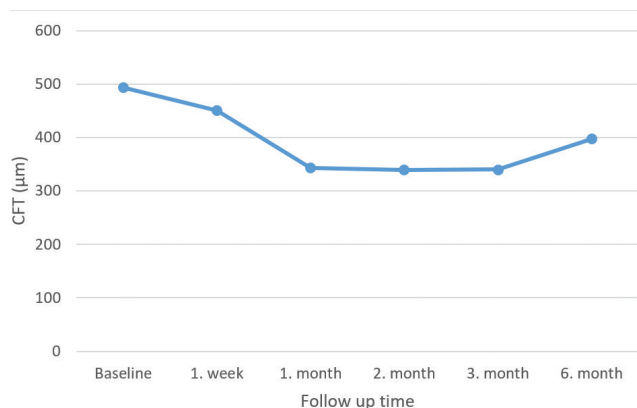
*According to baseline p value (ANOVA)

22-gauge tip, ready-to-inject injectable preparation containing 0.7 mg Dexamethasone, which can be effective for up to 6 months and is an FDA-approved drug in DME [13].

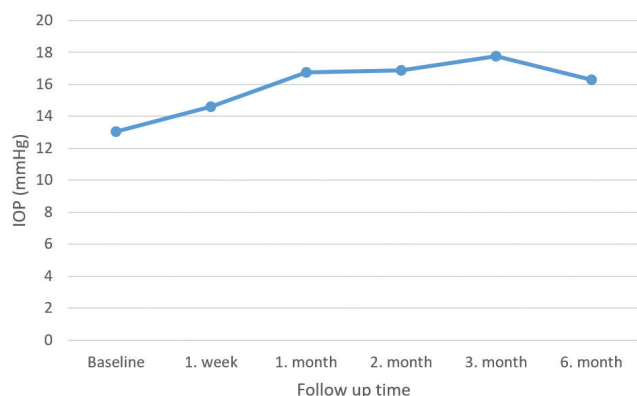
In the BEVORDEX study, a randomized, multicenter, phase 2 clinical trial comparing IVB and DEX-I treatments in the treatment of DME, it was reported that DEX-I provided better anatomical improvement with fewer in-



Graph 1. BCVA change graph before and after DEX-I treatment
BCVA – Best corrected visual acuity



Graph 2. CFT change graph before and after DEX-I treatment
CFT – Central foveal thickness



Graph 3. IOP change graph before and after DEX-I treatment
IOP – Intraocular pressure

jections compared to IVB, while providing similar visual improvement [17]. In our current study, we observed that DEX-I provided significant functional and anatomical improvement in DME refractory to IVB treatment, starting from the first week and continuing for 1,2,3 and 6 months. Similarly, in the RELDEX study, a real-life study, it was reported that DEX-I effectively treated DME under real-life conditions and had a good safety profile in long-term follow-up [18]. In the MEAD study, which is also a randomized sham-controlled phase 3 study, it was reported that 0.35 mg and 0.7 mg DEX-I injection had positive visual and anatomical effects in DME [19]. Similarly to our study, Totan et al. reported that DEX-I is a good alternative in DME resistant to IVB treatment, but this efficacy decreased between the 3rd and 6th months [20]. In our current study, we observed a decrease in functional and anatomical improvements between the 3rd and 6th months. This may be attributed to the fact that the release of DEX-I is highest in the first 3 months and then decreases and ends in the 6th month. Özata et al. reported that DEX-I treatment in IVR-resistant DME effectively increased BCVA and decreased CFT in the first 3 months in their study including 50 DME eyes of 38 patients [21]. Lazic et al. reported that DEX-I treatment is a good alternative treatment option in chronic DME not responding to IVB [22]. Yucel et al., in their 6-month follow-up retrospective study investigating the efficacy and safety of DEX-I in IVR-resistant chronic DME, reported that DEX-I was beneficial in terms of visual recovery and anatomical improvement in IVR-resistant DME [23]. Hatz et al. reported that DEX-I treatment repeated at a mean interval of 4 months was valuable in anti-VEGF-resistant DME [24]. Zhioua et al., including 13 eyes of 12 patients with DME, reported that DEX-I was effective in terms of visual recovery and anatomical improvement in DME that did not improve despite 6 consecutive months of IVR treatment [25]. Unlike our current study, Nalçacı et al., in their study investigating the 6-month results of single-dose DEX-I in IVR-resistant DME including 20 eyes of 14 patients, reported that DEX-I provided a significant CFT decrease at the end of 6 months, but there was no parallel improvement in BCVA [26]. Again, Koc et al. investigated the efficacy of DEX-I treatment in DME that did not improve despite 3 doses of anti-VEGF treatment and reported that there was no superiority between continuing the current anti-VEGF or switching to DEX-I after 3 doses of anti-VEGF [27]. OCT biomarkers such as serous macular detachment and hyperreflective spots are indicators of inflammation in DME [28]. Bonfiglio et al. reported that patients with DME unresponsive to IVR with serous macular detachment and hyperreflective spots on OCT responded better to DEX-I treatment [29].

In the IRGREL-DEX study, a multicenter, real-life study with 24-month follow-up, DEX-I was reported to provide better anatomical and functional improvement in patients with naive DME compared to refractory patients [30]. In the CHAMPLAIN study, it was reported that DEX-I 0.7 mg provided statistically and

clinically significant BCVA increase and reduction in vascular leakage in vitrectomized eyes with DME [31].

In our present study, IOP increased significantly at all follow-up visits compared to pre-DEX-I injection. However, ocular hypertension developed in only 3 eyes (0.8%) and was controlled with medical treatment. Mean IOP was 14.59 ± 1.83 mmHg before injection and 16.3 ± 2.51 mmHg 6 months after injection. In the MEAD study, a randomized, multicenter, 3-year, phase 3 study, the management and clinical significance of IOP elevation after DEX-I was investigated and IOP elevation was reported in approximately one-third of patients who underwent DEX-I [19]. In DME, 0.7 mg DEX-I, 0.35 mg DEX-I and sham injection were compared. In the DEX-I 0.7-mg group, 32% of the patients had IOP ≥ 25 mmHg, 15.3% had IOP ≥ 30 mmHg, and 6.6% had IOP ≥ 35 mmHg, while in the DEX-I 0.35 mg group, 27.4%, 14.6%, and 5.2%, respectively, and they reported that there was no significant difference between the two groups in terms of IOP elevation. They reported that repeated DEX-I injection had no cumulative effect on IOP. In the BEVORDEX study, it was reported that 45.7% of patients who received 0.7 mg DEX-I had IOP elevation above 5 mmHg and 19.6% had IOP elevation above 10 mmHg [17]. In the RELDEX study, IOP ≥ 25 mmHg was reported in 10.2% and IOP ≥ 35 mmHg in 2.3% of patients treated with DEX-I [18]. Totan et al., Lazic et al., Nalçacı et al. and Bonfiglio et al. reported the rates of IOP > 21 mmHg as 13.3%, 19%, 25% and 0.4%, respectively, in the follow-up of DME patients who underwent DEX-I [20,22,26,29].

In our current study, cataract progression was observed in 1% of patients with DME treated with DEX-I, and cataract surgery was performed in 2 patients. In the BEVORDEX study, it was reported that 13% of phakic pa-

tients treated with DEX-I had an increase of 2 grade or more in cataract density [17]. In the RELDEX study, cataract surgery was reported in 47% of patients treated with DEX-I [18]. It was reported that 70% of these patients underwent cataract surgery after the first injection, 22% after the second injection and 8% after the third injection. Akıncioğlu et al. reported that 50% of the patients had cataract progression and cataract surgery was required after an average of 5.4 ± 1.1 months after DEX-I in their 12-month follow-up study in which DEX-I was applied for DME [32]. Bansal et al., in a 24-month follow-up study in which DEX-I was administered for DME, reported that there was no cataract progression after the first injection and cataract progression developed in 11.5% of patients after the second injection [33]. Totan et al., Lazic et al., Nalçacı et al. and Bonfiglio et al. reported no cataract progression in their 6-month follow-up study in which DEX-I was administered for DME [20,22,26,29].

The limitations of our study include its retrospective nature, lack of comparison between DME types, lack of a separate classification and comparison of serous macular detachment and hyperreflective spots, which are inflammatory biomarkers in OCT, and short follow-up period.

CONCLUSIONS

DEX-I provided significant visual and anatomical improvement in refractory DME after 3 loading doses of IVB injections. DEX-I caused an acceptable IOP increase and cataract progression during the 6-month follow-up period. DEX-I is an effective and safe treatment option for DME refractory to IVB treatment.

REFERENCES

1. Bhagat N, Grigorian RA, Tutela A, Zarbin MA. Diabetic macular edema: pathogenesis and treatment. *Surv. Ophthalmol.* 2009;54(1):1-32.
2. Funatsu H, Noma H, Mimura T, Eguchi S, Hori S. Association of vitreous inflammatory factors with diabetic macular edema. *Ophthalmology.* 2009;116(1):73-79.
3. Funatsu H, Yamashita H, Noma H, Mimura T, Yamashita T, Hori S. Increased levels of vascular endothelial growth factor and interleukin-6 in the aqueous humor of diabetics with macular edema. *Am J Ophthalmol.* 2002;133(1):70-77.
4. Early treatment diabetic retinopathy study research group: photocoagulation for diabetic macular edema: early treatment diabetic retinopathy study report no 1. *Arch Ophthalmol.* 1985;103:1796-1806.
5. Liu XD, Zhou XD, Wang Z, Shen YM. Macular laser photocoagulation with or without intravitreal triamcinolone pretreatment for diabetic macular edema: a result from five randomized controlled trials. *Int J Ophthalmol.* 2016;9(1):132-138.
6. Michaelides M, Fraser-Bell S, Hamilton R, et al. Macular perfusion determined by fundus fluorescein angiography at the 4-month time point in a prospective randomized trial of intravitreal bevacizumab or laser therapy in the management of diabetic macular edema (Bolt Study): Report 1. *Retina.* 2010;30(5):781-786.
7. Nguyen QD, Brown DM, Marcus DM, et al. Ranibizumab for diabetic macular edema: results from 2 phase III randomized trials: RISE and RIDE. *Ophthalmology.* 2012;119(4):789-801.
8. Brown DM, Schmidt-Erfurth U, Do DV, et al. Intravitreal Aflibercept for Diabetic Macular Edema: 100-Week Results From the VISTA and VIVID Studies. *Ophthalmology.* 2015;122(10):2044-2052.
9. Yilmaz T, Weaver CD, Gallagher MJ, et al. Intravitreal triamcinolone acetate injection for treatment of refractory diabetic macular edema: a systematic review. *Ophthalmology.* 2009;116(5):902-913.
10. Martidis A, Duker JS, Greenberg PB, et al. Intravitreal triamcinolone for refractory diabetic macular edema. *Ophthalmology.* 2002;109(5):920-927.
11. Chan CK, Mohamed S, Lee VY, Lai TY, Shanmugam MP, Lam DS. Intravitreal dexamethasone for diabetic macular edema: a pilot study. *Ophthalmic Surg Lasers Imaging.* 2010;41(1):26-30.
12. Haller JA, Kuppermann BD, Blumenkranz MS, et al. Randomized controlled trial of an intravitreal dexamethasone drug delivery system in patients with diabetic macular edema. *Arch Ophthalmol.* 2010;128(3):289-296.
13. Boyer DS, Yoon YH, Belfort R Jr, et al. Three-year, randomized, sham-controlled trial of dexamethasone intravitreal implant in patients with diabetic macular edema. *Ophthalmology.* 2014;121(10):1904-1914.
14. Li H, Liu X, Zhong H, et al. Research progress on the pathogenesis of diabetic retinopathy. *BMC Ophthalmol.* 2023;23(1):372.
15. Chung YR, Kim YH, Ha SJ, et al. Role of Inflammation in Classification of Diabetic Macular Edema by Optical Coherence Tomography. *J Diabetes Res.* 2019;2019:8164250.

16. Noma H, Yasuda K, Shimura M. Involvement of Cytokines in the Pathogenesis of Diabetic Macular Edema. *Int J Mol Sci.* 2021;22(7):3427.
17. Gillies MC, Lim LL, Campain A, et al. A randomized clinical trial of intravitreal bevacizumab versus intravitreal dexamethasone for diabetic macular edema: the BEVORDEX study. *Ophthalmology.* 2014;121(12):2473-2481.
18. Malclès A, Dot C, Voirin N, et al. Real-life study in diabetic macular edema treated with dexamethasone implant: The Reldex Study. *Retina.* 2017;37(4):753-760.
19. Maturi RK, Pollack A, Uy HS, et al. Intraocular pressure in patients with diabetic macular edema treated with dexamethasone intravitreal implant in the 3-year mead study. *Retina.* 2016;36(6):1143-1152.
20. Totan Y, Güler E, Güragaç FB. Dexamethasone Intravitreal Implant for Chronic Diabetic Macular Edema Resistant to Intravitreal Bevacizumab Treatment. *Curr Eye Res.* 2016;41(1):107-113.
21. Özata K, Atum M, Çelik E, Doğan E, Alagöz G. Efficacy of intravitreal dexamethasone implant in persistent diabetic macular edema after primary treatment with intravitreal ranibizumab. *J Curr Ophthalmol.* 2019;31(3):281-286.
22. Lazic R, Lukic M, Boras I, et al. Treatment of anti-vascular endothelial growth factor-resistant diabetic macular edema with dexamethasone intravitreal implant. *Retina.* 2014;34(4):719-724.
23. Yucel OE, Can E, Ozturk HE, Birinci H, Sullu Y. Dexamethasone Implant in Chronic Diabetic Macular Edema Resistant to Intravitreal Ranibizumab Treatment. *Ophthalmic Res.* 2017;57(3):161-165.
24. Hatz K, Ebnetter A, Tuerksever C, Prunte C, Zinkernagel M. Repeated Dexamethasone Intravitreal Implant for the Treatment of Diabetic Macular Oedema Unresponsive to Anti-VEGF Therapy: Outcome and Predictive SD-OCT Features. *Ophthalmologica.* 2018;239(4):205-214.
25. Zhioua I, Semoun O, Lalloum F, Souied EH. Intravitreal dexamethasone implant in patients with ranibizumab persistent diabetic macular edema. *Retina.* 2015;35(7):1429-1435.
26. Nalçacı S, Akkin C, Afrashi F. Dexamethasone Implant in Patients with Diabetic Macular Edema Resistant to Anti-VEGF Therapy. *Turk J Ophthalmol.* 2019;49(2):73-77.
27. Koc H, Alpay A, Ugurbas SH. Comparison of the efficacy of intravitreal Anti-VEGF versus intravitreal dexamethasone implant in treatment resistant diabetic Macular Edema. *BMC Ophthalmol.* 2023;23(1):97.
28. Visioli G, Alisi L, Mastrogiuseppe E, et al. OCT biomarkers as predictors of visual improvement in diabetic macular edema eyes receiving dexamethasone implants. *Int J Retina Vitreous.* 2023;9(1):35.
29. Bonfiglio V, Reibaldi M, Pizzo A, et al. Dexamethasone for unresponsive diabetic macular oedema: optical coherence tomography biomarkers. *Acta Ophthalmol.* 2019;97(4):e540-e544.
30. Iglicki M, Busch C, Zur D, et al. Dexamethasone implant for diabetic macular edema in naive compared with refractory eyes: The International Retina Group Real-Life 24-Month Multicenter Study. *The IRGREL-DEX Study. Retina.* 2019;39(1):44-51.
31. Boyer DS, Faber D, Gupta S, et al. Dexamethasone intravitreal implant for treatment of diabetic macular edema in vitrectomized patients. *Retina.* 2011;31(5):915-923.
32. Akıncioğlu D, Küçükercilioğlu M, Durukan AH, Aykaş S, Ayyıldız Ö, Erdurman FC. Outcomes of Intravitreal Dexamethasone Implant in the Treatment of Recalcitrant Diabetic Macular Edema. *Turk J Ophthalmol.* 2017;47(5):274-278.
33. Bansal P, Gupta V, Gupta A, Dogra MR, Ram J. Efficacy of Ozurdex implant in recalcitrant diabetic macular edema--a single-center experience. *Int Ophthalmol.* 2016;36(2):207-216.