

Easy Method of Pterygium Excision using Autologous Blood for Conjunctiva Autograft Fixation

Silitonga Andrea Radotma¹,
Silitonga Hanna Tabita Hasianna²

¹SMEC Eye Hospital Medan, Indonesia

²Departement of Public Health, Preventive Medicine and Community Medicine, School of Medicine, Universitas Ciputra Surabaya, Indonesia



First author

Dr. Andrea Radotma Silitonga

Corresponding author

Dr. Hanna Tabita Hasianna Silitonga
Department of Public Health, Preventive Medicine and Community Medicine
School of Medicine, Universitas Ciputra Surabaya
CitraLand CBD Boulevard
Surabaya 60219
Indonesia
E-mail: hanna.silitonga@ciputra.ac.id

Submitted to the editorial board: July 27, 2024

Accepted for publication: November 8, 2024

Available on-line: January 17, 2025

The authors of the study declare that no conflict of interest exists in the compilation, theme and subsequent publication of this professional communication, and that it is not supported by any pharmaceutical company.

SUMMARY

Aims: This study was planned to explore the efficacy of autologous blood as a stabilizing agent for graft surgery in pterygium.

Material and Methods: For this observational, non-comparative, interventional study, the hospital data of patients who underwent pterygium surgery with autografting using autologous blood between October 2021 to March 2022 were retrospectively analyzed. The graft stability post-surgery and recurrence was studied. There were 37 eyes of 37 patients undergoing pterygium surgery with autograft using autologous serum. The mean age was 53.5 ± 10.10 years.

Results: Pterygium included were nasal sided primary grade 3 pterygium, double-head pterygium and recurrent pterygium. Postoperatively, there were 4 cases of graft loss (10.8%). The mean time of follow up was 1.8 ± 1.4 months (range 1 to 5 months). There was no recurrence seen in patients with graft intact.

Conclusion: Autologous blood is a good and cost-effective stabilizing agent for graft surgery in pterygium.

Key words: autologous blood, conjunctiva autograft fixation, pterygium excision

Čes. a slov. Oftal., 81, 2025, No. 4, p. 206–211

INTRODUCTION

Fibrovascular proliferation and elastotic degeneration of the subconjunctival tissue is defined as pterygium. This disease is more commonly seen in tropical countries where exposure to UV sunlight is high, as it may damage the limbal stem cells and activate matrix metalloproteinase [1]. Small pterygium usually gives no symptoms, but large pterygium can be an indication for pterygium excision, because of decreased visual acuity resulting from visual axis involvement, irregular astigmatism, tear film breaks up, and/or irregular eye movement limitation, eye irritation and discomfort, inability to wear contact lenses, difficulty in performing refractive surgery and cosmetic concern [2].

Pterygium that has already invaded the cornea is one of the indications of surgery. There are several surgical

approaches and adjuvant usage in treating pterygium, which include simple excision, bare sclera technique, amniotic membrane transplantation, autorotation of conjunctival flap and conjunctival autografting. The recurrence rate varies according to the type of surgery done. Bare sclera technique is associated with high recurrence rates around 24–89% [1–3].

Adjuvant measures following pterygium excision, such as mitomycin C (MMC), beta-irradiation, and thiotepea, have been used to reduce recurrence rates [4,5]. MMC has shown effectiveness in reducing recurrence rates compared to beta-irradiation. However, these adjuvant therapies are associated with potential complications. Beta-irradiation can lead to scleral ulceration, infection, and cataract [5]. MMC use has been linked to serious ocular complications, including secondary glaucoma,

corneal edema, iritis, cataract, and scleral infection [4]. Notably, scleral stromalysis has been reported as a long-term complication of MMC use, presenting anywhere from months to years after application [6]. Due to these potential sight-threatening complications, the use of MMC and beta-irradiation should be approached with caution, and long-term follow-up is essential [5,6].

The gold standard for pterygium surgery, especially large or recurrent pterygium, is pterygium excision with conjunctival autografting, by which the recurrence rate can be minimized (2–9%) with relatively few sight-threatening complications [3]. There are various methods used for graft fixation. Sutures, fibrin glue, and autologous blood have been compared in several studies. Sutures have some suture-related complications, such as prolonged surgical time, postoperative discomfort, infection, chronic inflammation, irritation, suture-induced conjunctival granuloma, and have even shown higher recurrence rates in some cases compared to autologous blood fixation [7]. Autologous blood fixation offers advantages, such as reduced irritation, lower infection risk, and cost-effectiveness. However, graft loss and retraction

were reported as potential complications [7,8]. A meta-analysis found that autologous blood was inferior to fibrin glue in terms of surgical duration, graft retraction, and displacement, but showed no significant difference in recurrence rates [9]. Fibrin-based adhesives may be used under the autograft without inducing much inflammation because of its biological and biodegradable properties. The use of fibrin glue improves postoperative comfort, decreases surgical time and complications. High cost of fibrin glue, the risk of transmission of prion disease through plasma-derived fibrin glue and the risk of anaphylaxis in susceptible individuals are the major limiting factors in this mode of treatment [8,9]. A recent popular method is graft fixation with the patient's own autologous serum, which is used as tissue adhesive for securing the conjunctival autograft. This method is cost-effective and can also reduce suture- or glue-related complications [4].

At the point when human tissue is harmed, bleeding follows. When the coagulation cascade is set on, enacted factor X specifically hydrolyzes prothrombin to thrombin; fibrinogen is changed over completely to fibrin. Throm-

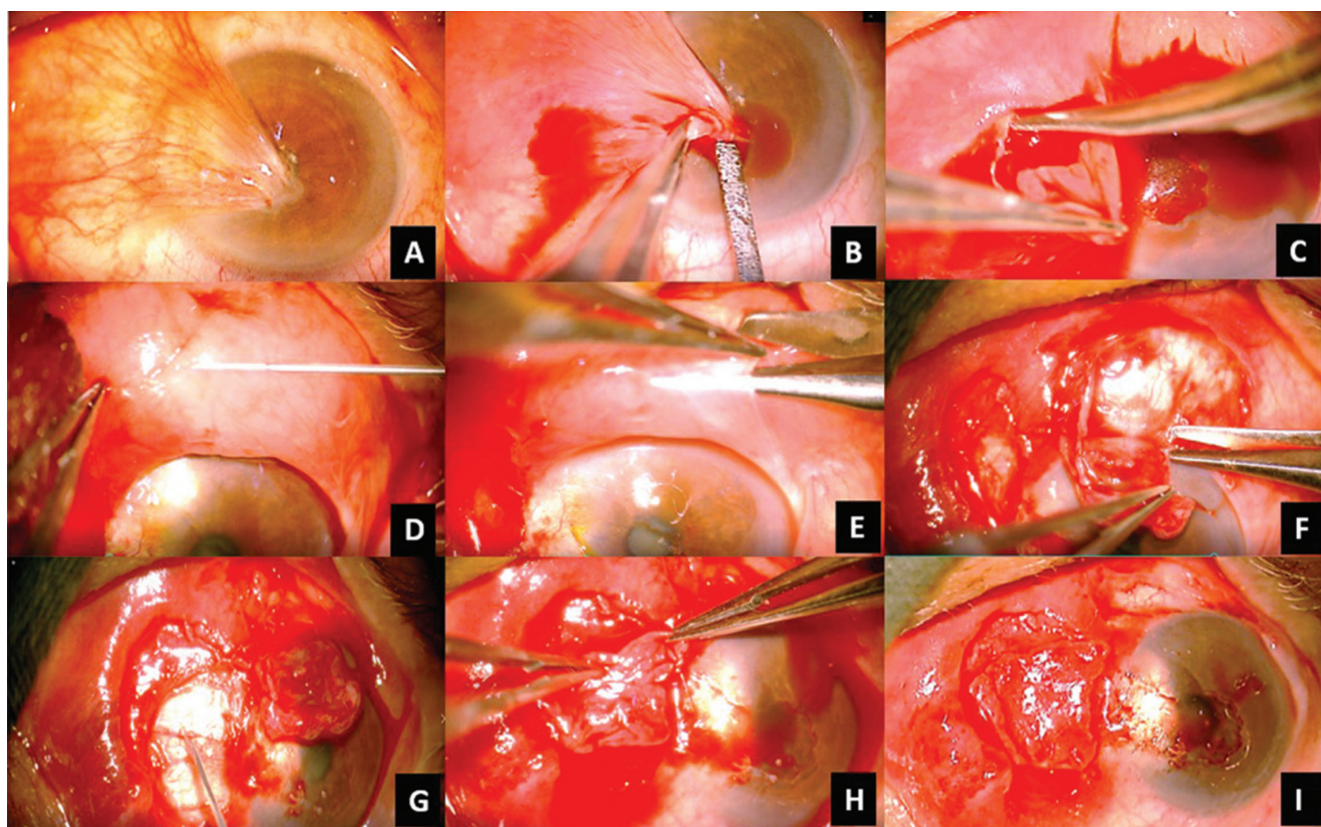


Figure 1. Pterygium grade 4 excision and conjunctiva autografting (A). After topical and subconjunctival anesthesia, the head of pterygium was bluntly dissected from the cornea using toothed forceps and iris spatula (B). The body of pterygium was cut-off using Westcott scissor, carefully blunt dissected the conjunctiva from the body pterygium below and the tenons, in order to reserve as much conjunctiva as possible and removes as much as possible the body pterygium and tenons (C). Subconjunctival lidocaine was used to ballooning the inferior conjunctiva (D). Graft was taken using Westcott scissor (E), as thin as possible and not including too much tenons capsule (F). The scleral bed should be dry, free of tenons, and surgeon can nick some episcleral vessels to make new and fresh blood (G). The graft was cut off and placed onto the scleral bed while maintaining limbal to limbal orientation (H). The graft was left for 5 minutes to attach, excessive blood was taken away using cotton bud tip. No saline irrigation is allowed during this waiting time, except few drops of saline directly to cornea (I).

bin additionally activates factor XIII, which settles the coagulation, by advancing polymerization and cross-connecting of the fibrin chains into long fibrin strands within the presence of calcium ions. This is the normal pathway for both intrinsic and extrinsic pathways of coagulation *in vivo*. This mechanism is utilized to prompt tissue adherence of the Conjunctiva Autologous Graft (CAG) to uncovered sclera [5,6]. The graft adheres in light of the fibrinous response in the patient's own blood (serum). The current review aims to observe the adequacy of autologous blood as a bio-adhesive agent for securing CAG in pterygium excision.

MATERIALS AND METHODS

This observational study was conducted at the outpatient SMEC Eye Hospital Medan from October 2021 to March 2022. The study included 37 eyes of 37 patients with primary pterygium grade 3 or 4 or recurrent pterygium that was scheduled for pterygium excision and conjunctival autograft. However, patients with a history of ocular surface infections, ocular trauma, bleeding abnormalities, and anticoagulant therapy were exempted from the study. The study was approved by the hospital's Ethical and Research Committee.

Demographic data including age, gender, and complaints of all the patients were documented. Visual acuity was measured by Snellen's chart and best corrected visual acuity was recorded. A detailed anterior segment examination was performed under slit-lamp biomicroscope for diagnosis of pterygium, and characteristics such as, grade, type, and site were recorded. Pterygium was graded according to corneal involvement as: grade 1 (crossing the limbus), grade 2 (midway between the limbus and pupil), grade 3 (reaching up to the pupillary margin) and grade 4 (crossing the pupillary margin). Patients with both nasal and temporal pterygium in the same eye were diagnosed as "double-headed pterygium".

All surgical procedures were done under topical anesthesia (2% tetracaine eyedrop). All surgeries were done under a microscope by the same single surgeon using the same technique (Figure 1). Taking all aseptic precautions, the eyelid was then separated by a speculum, and a sub-conjunctival and subpterygial 0.5 ml lidocaine solution was injected. Gentle massage over the lesion was applied by a cotton-tipped applicator for a few seconds. The neck of the pterygium was then lifted up with the help of fine-toothed forceps, while the head of the pterygium was gently blunt-dissected from the cornea by placing an iris spatula underneath the neck of the pterygium mass, keeping the same constant tractional force throughout. After the pterygium head was detached from the cornea, gentle dissection was then carried out in between the conjunctiva and the sclera with the help of a cotton bud, to resect at least 4–5 mm of the pterygium mass that included both the superior and inferior borders, ensuring that the scleral bed was free from tenons. No cauterization

was used throughout the surgery. Tamponade with a cotton bud or saline irrigation was used accordingly if there was active bleeding that obscured the surgical view. The size of the bare sclera defect was then measured with Castroviejo calipers. Corneal care was taken by applying several drops of saline or viscoelastic throughout the procedure. Harvesting the graft was done by ballooning the superior or inferior conjunctiva with 0.5 ml lidocaine 2%. Corneal scissors were used to make a fine film of 0.5–1 mm oversized, free conjunctival graft, carefully avoiding inclusion of tenon, or making a buttonhole within it. Before attaching the graft, the scleral bed must be free from tenons and clotted blood. In the clean and dry bare sclera, some episcleral blood vessels were punctured for new blood to appear (not too much). The graft was then placed over the bare sclera, ensuring the same limbus to limbus orientation. We waited for 5 minutes for hemostasis to occur. No saline irrigation was allowed at this point. Excess blood was wiped away gently, using a cotton bud tip. However, corneal drying was prevented by wetting the cornea with normal saline drop by drop. During waiting time, the graft was pressed gently on to the scleral bed, using a rolling movement of a cotton bud tip, making sure that there was no gap between the graft and the sclera. After 5 minutes, the attachment of the graft was checked by gently touching it with a cotton bud tip and asking the patient to look to the right and the left repeatedly. If there was graft movement or displacement, the graft was left for more time to attach. After the graft was attached firmly, subconjunctival gentamicin might be given at the other site of the bulbar conjunctiva away from the graft site. Eye ointment or drops should be avoided. The eye speculum was then carefully taken away, the eye was closed, and a bandage pad applied. It is best to leave the eye bandaged for a minimum of 24 hours and better for 48 hours. During this time, the patient was given oral analgesics. After 24–48 hours, the pad and bandage were carefully opened and subconjunctival hemorrhage, graft displacement, graft edema and graft loss were looked for. Postoperatively, the patient was put on a topical antibiotic and steroid combination for the first 2 weeks, tapering it thereafter over the next 4 weeks. The patient was asked to attend on postoperative Days 7 and 30. At each postoperative visit, thorough slit-lamp examination, tonometry was done, and any recurrence, complication(s), or any complaints were recorded.

The data were entered in Microsoft Excel. We calculated the means and standard deviations for the linear variables and proportions for categorical variables.

RESULTS

A total of 37 patients were included in the study. There were 26 (70.3%) female and 11 (29.7%) male patients. The mean age group was 53.5 ± 10.10 years. Most of the pterygium was grade 3 pterygium (72.8%), including 2 eyes of

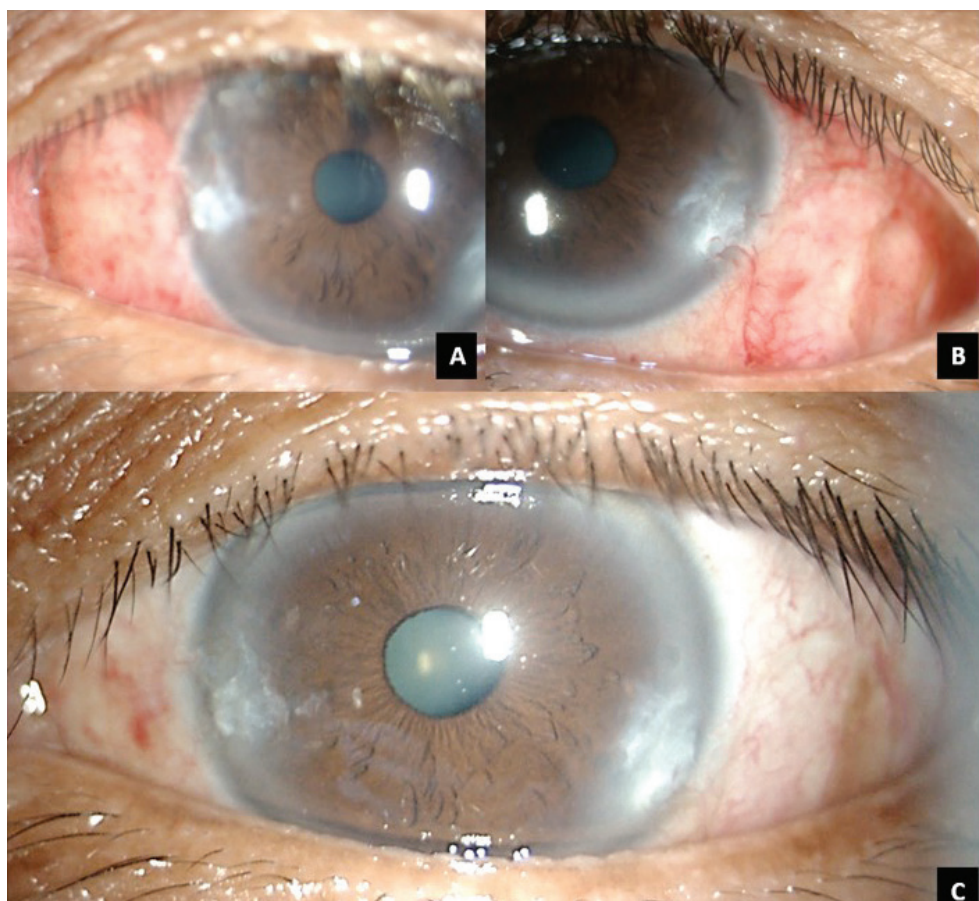


Figure 2. Post operative day 2 of a double headed grade 3 pterygium. Graft was taken from the superior and inferior side of conjunctiva to be placed in the nasal (A) and temporal (B) side of pterygium. Graft was attached with minimal oedema and subconjunctival hemorrhage. Picture (C) was the same eye taken after one week post-surgery. Graft was well tolerated and already fused with the conjunctiva.

Table 1. Clinical Characteristics

Characteristics	Number, percentage, mean \pm Standard Deviation	Range
Gender (n = 37)		
Male	11 (29.7%)	-
Female	26 (70.3%)	-
Age (years)	53.5 \pm 10.10	32 to 72
Pterygium grade		
Grade 3	27 (72.8%)	-
Grade 4	8 (21.6%)	-
Reccurent	2 (5.6%)	-
Duration of follow up (months)	1.8 \pm 1.4	1 to 5

Table 2. Complication Post Operative

Complication	Post Operative Day 1–2	Post Operative Day 7	Post Operative Day 30
Graft loss	4 (10.8%)	-	-
Graft displacement	2 (5.4%)	-	-
Graft edema	20 (54%)	1	-
Graft retraction	1 (2.7%)	-	-
Reccurance	none	none	none

grade 3 double-headed pterygium. 8 eyes were pterygium grade 4 (21.6%), including 2 eyes of grade 4 double-headed pterygium. There were 2 cases of recurrent pterygium (1 eye with grade 3 pterygium and 1 eye with grade 4 pterygium). The demographic profile is given in Table 1.

The postoperative complications are given in Table 2. Postoperatively, the most common complication was graft edema that occurred in 20 (54%) eyes. However, after postoperative Day 7, only 1 eye still had persistent graft edema, and no eyes had graft edema on postoperative Day 30. There were 4 cases (10.8%) of graft loss. In the case of graft loss, the patient was asked whether to have a revision done or medication only. All patients with graft loss opted for medication only and refused graft revision.

Graft attachment was observed in 33 eyes (89.2%) after 24-48 hours of postoperative patching (Figure 2). Other most common complications were graft edema in 20 (54%) eyes and graft displacement in 2 (5.4%) eyes (Figure 3). However, after postoperative Day 7, only one eye still had persistent graft edema, and no eyes had graft edema on postoperative Day 30. The patients were followed for 1-5 months and there was no recurrence observed in patients with attached grafts.

DISCUSSION

Many previous studies suggest that the prevalence of pterygium was higher in the male than the female gen-

der [1-3]. In our study, we have seen a higher prevalence of pterygium in females (62%). A reason for the higher prevalence could be greater cosmetic awareness among women and greater outdoor exposure of women in tropical suburban areas to earn a livelihood than men. Most patients in the present study were in the middle-age group (mean 53.5 years old).

In our study, there was a 10.8% (4 eyes) graft loss rate. The possible explanation for the graft loss may be due to 1) shorter duration of patching the eye postoperatively; 2) thick graft that included too much subtenon; 3) excessive eye movement; 4) not enough fibrin compound of blood. Ratnam *et al.* patched the patients for 48 hours and experienced no graft loss [12]. In our patients, those patients that experienced graft loss mostly could only be patched for 12-18 hours for various reasons (living far from the hospital or could not visit the hospital for Day 2 follow-up). One limitation of autologous blood usage as bio-adhesive is that the component of each person's blood varies. That being said, clotting time or thrombin time might vary from person to person. One person with ideal thrombin and fibrinogen might experience no difficulty in graft attachment. However, if there was not sufficient fibrinogen or thrombin component, the clotting cascade might be delayed or need longer time. It is important to evaluate the attachment of the graft during surgery. Only if good adhesion is found, can the eye be closed and patched [4].

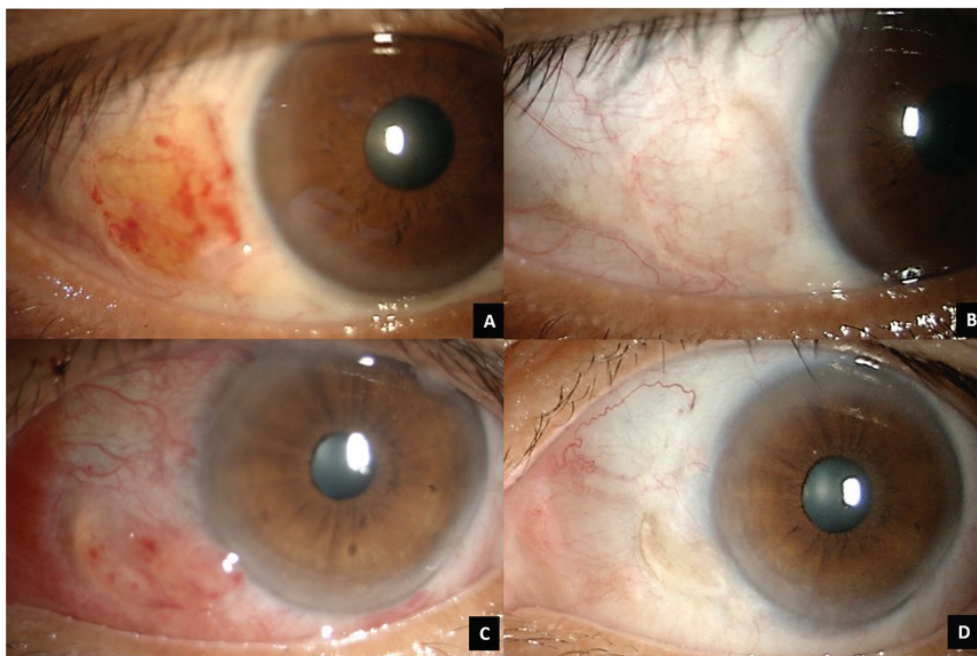


Figure 3. Complication of post operative day 7 of a pterygium grade 3 excision with autograft conjunctiva using autologous blood. Graft showed slight edematous and there was blood under the graft with yellowish tint of supposedly fibrin (A). After 4 weeks, the graft was well tolerated and already fused with conjunctiva (B). Graft displacement can be seen in another patient (C), showed the graft was displaced inferiorly leaving a bare sclera superiorly. The patient did not want a revision procedure and opted for medication only. (D) After 4 weeks, the displaced graft still can be seen and fused with the rest of conjunctiva. No sign of recurrence was seen.

Graft edema was frequently found on postoperative Day 1 or 2. This study found that over 50% of patients had graft edema, however it was reduced to one patient only on postoperative Day 7. Inadequate dissection of pterygium tissue which led to thick grafts due to persistent Tenon's capsule in some patients was the most frequent cause of graft edema. Furthermore, poor compliance with the instillation of steroid eye drops was also the cause of persistent graft edema [1,4–6].

Graft retraction was seen in 1 (2.7%) patient in autologous blood conjunctiva autograft. This is due to mismatch of graft size, since the graft usually shrinks if it was not properly stretched out. It is better to have an oversized graft by 0.5–1 mm to avoid graft retraction. Care must be taken to acquire the thin and appropriate size of graft when performing surgery with the autologous blood technique [1,2,7].

In our study, graft displacement was seen in 2 patients. Graft displacement mostly occurred within 24 to 48 hours of surgery. It is considered that the graft usually displaces due to excessive rubbing of the operated eye due to a foreign body sensation. Proper counselling of patients not to rub their eyes avoids complications related to graft displacement [5,6].

The result of the conjunctiva autograft with autologous blood in this study was comparable to other studies with similar techniques, either using sutures of commercial fibrin glue [1,2,4–7]. A sutureless and glue-free conjunctival autograft using blood clot as a bio-adhesive is a useful alternative method for graft fixation in pterygium surgery. A suture- and glue-free autologous graft has no

extra cost or associated risks and can overcome the post-operative irritation, pain and foreign body sensation to a great extent [5,6]. The procedure is cosmetically better. The opposition of the lids to the bulbar conjunctiva provides a natural biological dressing and confers a unique wound healing environment. The main disadvantage of this method is the risk of the graft getting lost in the immediate post-operative period [1,2,4,6,7].

The limitation of this study is that there is no comparison to other techniques, and only a short follow-up of patients, so the exact rate of recurrence is obscure. The number of patients was also limited. In this study, we also included recurrent pterygium and double-headed pterygium as proof that this technique is reproducible and can be carried out in difficult pterygium as well.

CONCLUSION

Pterygium excision and conjunctival autograft with autologous blood is a viable and better surgical option for management of primary as well as recurrent pterygium. The feasibility of adherence of the graft without glue and sutures is promising. The potential risks associated with the use of fibrin glue and suture-related problems can be avoided with this technique. This procedure has an excellent outcome. It is cost-effective, time-saving, easy to perform and safe for patients, with a good cosmetic outcome.

Acknowledgements:

We would like to thank all respondents who participated in this research.

REFERENCES

1. Krishnadas D, Mohan S, Muni R, Al. E. A multivariate analytical study on surgical outcomes of pterygium excision and conjunctival autograft fixation by autologous serum vs. sutures in a tertiary eye care centre. *J Evid Based Med Heal*. 2020;7(29):1408-1413.
2. Beesam K, Krishna N. Autologous blood as tissue adhesive for conjunctival autograft in primary nasal pterygium surgery. *J Pre-Clin Clin Res*. 2018;12(2):51-53.
3. Ram A, Babu S, Amaresh G. Comparative study of recurrence rate of pterygium excision with bare sclera technique and conjunctival autograft in Nalgonda Dist. *J Evol Med Dent Sci*. 2013;2(18):3025-3030.
4. Thakur SK, Khaini KR, Panda A. Role of low dose mitomycin C in pterygium surgery. *Nepal J Ophthalmol*. 2012 Jan-Jun;4(1):203-205. doi: 10.3126/nepjoph.v4i1.5881
5. Amano S, Motoyama Y, Oshika T, Eguchi S, Eguchi K. Comparative study of intraoperative mitomycin C and beta irradiation in pterygium surgery. *Br J Ophthalmol*. 2000 Jun;84(6):618-621. doi: 10.1136/bjo.84.6.618
6. Lindquist TP, Lee WB. Mitomycin C-associated scleral stromalysis after pterygium surgery. *Cornea*. 2015 Apr;34(4):398-401. doi: 10.1097/ICO.0000000000000384
7. Suryawanshi MP, Isaac R, Suryawanshi MM. Pterygium excision with conjunctival autograft fixed with sutures, glue, or autologous blood. *Oman J Ophthalmol*. 2020 Feb 17;13(1):13-17. doi: 10.4103/ojo.OJO_113_2019
8. Patkar P, Shrivastava S, Ramakrishnan R, Kanhere M, Riaz Z. Comparison of fibrin glue and autologous blood for conjunctival autograft fixation in pterygium. *Kerala J Ophthalmol*. 2017;29:86-90.
9. Rekha B, Girimallanavar S. Efficacy of autologous fibrin glue versus sutures for conjunctival autograft in pterygium surgery: A 1-year randomized controlled study. *J Clin OphthalmolRes*. 2020;8:24-29.
10. Zeng W, Dai H, Luo H. Evaluation of Autologous Blood in Pterygium Surgery With Conjunctival Autograft. *Cornea*. 2019 Feb;38(2):210-216. doi: 10.1097/ICO.0000000000001798
11. Kumar P, Pandey S, Titiyal G, Satyawali V. Post-operative outcomes of pterygium surgery using autologous blood and sutures: A comparative study. *IP Int J Ocul Oncol Oculoplasty*. 2016;2(2):114-118.
12. Ratnam P, Vijetha P. The autologous blood become gold standard procedure in pterygium surgery: An observational study. *Indian J Clin Exp Ophthalmol*. 2018;4(1):127-130.