

Evaluation of morphological changes in the retina using OCTA in patients with diabetic macular edema treated with anti-VEGF using ImageJ

Beran David, Hejsek Libor, Studnička Jan

Department of Ophthalmology, University Hospital Hradec Králové, Czech Republic. Department of Ophthalmology, Faculty of Medicine in Hradec Králové, Charles University, Czech Republic



MUDr. David Beran

Submitted to the editorial board: February 12, 2025

Accepted for publication: March 26, 2025

Available on-line: June 6, 2025

The authors of the study declare that no conflict of interests exists in the compilation, theme and subsequent publication of this professional communication, and that it is not supported by any pharmaceuticals company. The study has not been submitted to any other journal or printed elsewhere, with the exception of congress abstracts and recommended procedures.

Correspondence address:

Oční klinika Fakultní nemocnice Hradec Králové
Sokolská 581
500 05 Hradec Králové
Czech Republic
E-mail: david.beran@fnhk.cz

SUMMARY

Aim: To evaluate changes in the vascular density of the deep and superficial capillary plexus of the retina, the area of the foveal avascular zone, central retinal thickness, and best corrected visual acuity in patients with diabetic macular edema treated with anti-VEGF agents.

Material and Methods: In a prospective study at the Ophthalmology Clinic of FNHK, we evaluated a group of 41 eyes of 30 patients (19 men and 11 women) with diabetic macular edema treated with Lucentis or Eylea. The average age of the patients was 61.7 ± 11.3 years. Average initial visual acuity was 64.4 ± 9.1 letters on ETDRS optotypes. During the one-year follow-up period we monitored the density of the deep and superficial retinal capillary plexus using OCTA. We evaluated OCTA scans with the ImageJ program at 3, 6, 9, and 12 months. Additionally, the area of the foveal avascular zone, central retinal thickness, and best-corrected visual acuity were measured.

Results: During the one-year follow-up period there was a statistically significant change in both retinal capillary plexuses, with the density of the deep capillary plexus increasing ($p < 0.0001$) and the superficial capillary plexus decreasing ($p = 0.0073$). The area of the foveal avascular zone decreased from an initial average value of $0.29 \pm 0.14 \text{ mm}^2$ to $0.24 \pm 0.07 \text{ mm}^2$ ($p = 0.0406$). Average central retinal thickness decreased from $434.1 \pm 96.2 \text{ }\mu\text{m}$ to $322.2 \pm 90.8 \text{ }\mu\text{m}$ ($p = 0.0001$). Best corrected visual acuity improved by 7.3 letters on ETDRS optotypes over the year ($p < 0.0001$).

Conclusion: Treatment with the aforementioned anti-VEGF agents significantly reduces central retinal thickness and improves visual acuity in patients. It affects the density of the retinal capillary plexuses and the area of the foveal avascular zone. The results of the impact of anti-VEGF agents on macular perfusion vary considerably in the available meta-analyses. The design of the study, the approach to assessing the density of the retinal capillary plexuses, the number and characteristics of patients (including inclusion and exclusion criteria), the duration of the follow-up period, and the specific anti-VEGF agents used are all influential factors.

Key words: diabetic macular edema, anti-VEGF, optical coherence tomography angiography, ImageJ

Čes. a slov. Oftal., 81, 2025, No. x, p.

INTRODUCTION

The human retina has the greatest metabolic demands of all the tissues in the body. Due to its highly specialized activity, the capacity to regulate blood flow is a fundamental and complex feature of the retina in mammals. Histological findings have identified four different retinal capillary plexuses, only three of which are localized within the macular region: the superficial, deep and intermediate capillary plexus. The capillaries in the retinal nerve fiber layer and the ganglion cell layer form the inner (or superficial) capillary plexus (SCP), while the inner and outer plexiform layers receive blood from the deep capillary plexus (DCP), which is located on their junction [1].

Diabetic macular edema (DME) is the most common cause of deterioration of visual acuity (VA) in patients with diabetic retinopathy (DR), and represents a serious health and socio-economic problem. Approximately 7% of patients with diabetes suffer from diabetic macular edema. The pathogenesis of DME is multifactorial, and its onset and progression are contributed to primarily by hyperglycemia, as well as hyperlipidemia and systemic hypertension. Chronic hyperglycemia results in damage to the endothelial cells (inner blood-retinal barrier (BRB)) of the retinal capillaries. In addition to disorder of the BRB, the development of DME is also influenced by an increased level of vasoactive factors in the eye and the state of the vitreoretinal interface [2,3].

A typical feature of DME is accumulation of fluid in its anatomically predisposed central part of the retina – the macula, either inside the cells or extracellularly in the outer plexiform and inner nuclear layer [4,5].

The cause of onset of intracellular edema is a change of distribution of cellular ions, which results in an excessive accumulation of sodium ions inside the cells with subsequent hyperosmolar swelling. Extracellular edema is mainly associated with a disorder of the inner and outer BRB [6].

Vascular endothelial growth factor (VEGF) plays an important role in the pathophysiology of DME. In an environment with a high blood glucose level, products of glycosylation increase and active oxygen is on a relatively high level, which leads to further production of diglycerides. This activates protein kinase C, which mediates the formation of VEGF. VEGF is the primary regulating factor of neovascularization and vascular permeability, which characterizes DME. Interaction of the vascular receptors on the surface of the endothelial cells may be deactivated by means of VEGF inhibition in order to prevent hyperplasia of the vascular endothelium, thereby reducing retinal neovascularization and infiltration of the blood vessels in the macular region [7].

In clinical practice, an unsatisfactory response to treatment has been recorded in some patients with DME, which indicates that the correlation between DME and diabetic macular ischemia (DMO) may reduce response to therapeutic modalities of macular edema, with persistence of long-term accumulation of fluid [8].

MATERIAL AND METHOD

The cohort included patients who were treated at the Ophthalmology Clinic of FNHK from March 2019 to March 2022. During the course of the one-year prospective follow-up period, our cohort consisted of 41 eyes of 30 patients, who underwent regular follow-up examinations in the 3rd, 6th, 9th and 12th month of treatment. The cohort comprised 19 men (63.3%) and 11 women (36.3%) with an average age of 67.1 ± 11.3 years. The cohort was composed predominantly of patients with type 2 diabetes (93.3%). Six patients (20%)

were being treated with insulin therapy, 12 patients with oral antidiabetic drugs (40%) and 12 patients with combined therapy. The mean value of HbA1c upon commencement of therapy was 59.3 ± 8.8 mmol/mol. DME was treated with ranibizumab (30% of patients) or aflibercept (60% of patients). During the one-year observation period an average of 7.7 ± 1.9 injections were applied. The study included only patients who had met the indication criteria for coverage of the anti-VEGF preparation by their health insurance company. At the commencement of treatment, all the patients therefore had glycated hemoglobin (HbA1C) lower than 70 mmol/mol, VA within the range of 6/12 to 6/30 or 6/12 to 6/48 in the case of one seeing eye, central retinal thickness was greater than 300 μ m on OCT and the period of duration of macular edema did not exceed 2 years. The patients had not received any other anti-VEGF therapy in the preceding period (treatment naive). We excluded from the study patients who had undergone pars plana vitrectomy (PPV), glaucoma patients with limitation of the visual field on the perimeter, patients with a finding of advanced cataract which was influenced by OCTA examination, and patients with any other pathology in the macula. The details with the demographic data of the patients are summarized in Table 1.

The OCTA instrument Spectralis (Heidelberg engineering) was used for examination of the retina, in which an angiographic examination of the deep and superficial capillary plexus of the retina was conducted with measurement of central retinal thickness (CRT). The scans were obtained in high resolution mode (2.8 x 2.8 mm), using the follow-up function, which ensured scanning of the same region of the retina in the given patient.

The foveal avascular zone was measured on the Spectralis instrument with the aid of the Draw region function. For calculation of the change in density of the capillary plexuses we used the ImageJ software developed by the National Institutes of Health and the Laboratory for Optical and Computational Instrumentation (University of Wisconsin).

ImageJ and its use

The program is used primarily for processing biomedical images. In our study, after inserting the image from the OCTA into ImageJ in jpeg. format, we adjusted the image so that the same surface was assessed for each patient (cropping of image to 980 x 980 pixels) without any loss of data. We also used the „make binary“ function to create a black and white raster. A histogram was then created from this raster, which enabled us to display the sum of pixels in the image (white pixels – vasculature of retina, black pixels – background). The change of the sum of these pixels was assessed over time as the change of density of the capillaries in the retina. Figure 1.

In the statistical evaluation all the groups of values were tested in the program GraphPad Prism (GraphPad Software Inc.) for normality (Anderson-Darling, Shapiro-Wilk, Kolmogorov-Smirnov tests) and subsequently assessed using a parametric (T-test) or non-parametric test (Wilcoxon test, Friedman test). The level of significance of the test was set at 0.05.

All the patients signed an informed consent form for participation in the study and the administration of the active agent intravitreally in accordance with the Helsinki Declaration.

Table 1. Baseline demographic and clinical characteristics

Demographic data of patients	all (n = 30)
Gender, females, n (%)	11 (36.3 %)
Average age (years) \pm SD	67.1 ± 11.3
Average visual acuity, number of ETDRS letters \pm SD	63.4 ± 9.1
Average central retinal thickness, μ m \pm SD	434 ± 96.3
Number of patients treated with insulin, n (%)	6 (20 %)
Number of patients treated with OAD, n (%)	12 (40 %)
Number of patients on both insulin and OAD (%)	12 (40 %)
Average HbA1c value (mmol/l) \pm SD	59.7 ± 8.9

n – number of eyes, DM – diabetes mellitus, ETDRS – Early Treatment Diabetic Retinopathy Study, SD – standard deviation, OAD – oral antidiabetic drugs, HbA1c – glycated hemoglobin

RESULTS

Development of best corrected visual acuity (BCVA)

Average initial BCVA in the patients was 63.4 ± 9.0 letters on ETDRS optotypes. During the course of therapy we recorded a deterioration of VA by more than 5 letters on ETDRS in only 3 eyes (7.3%), and an improvement of BCVA by more than 5 letters in 25 eyes (60.9%). During the course of the year there was a statistically significant improvement of BCVA by 7.3 letters ($p < 0.0001$) to 70.7 ± 12.5 letters. Graph 1.

Development of central retinal thickness

Average initial CRT in the patients was $434.1 \mu\text{m} \pm 96 \mu\text{m}$. After one year of observation it was statistically significantly reduced to $322.2 \mu\text{m} \pm 90 \mu\text{m}$ ($p = < 0.0001$). We recorded the sharpest decrease of CRT in the interval of 0–3 months, when at the end of this interval CRT was

CRT $370 \mu\text{m} \pm 93.16$. An increase of CRT after the one-year observation period was recorded in 3 eyes (7.3%). Graph 2.

Development of density of retinal capillary plexuses

The superficial and deep capillary plexuses were assessed with the aid of ImageJ software. After 12 months we determined statistically significant changes in both of the above. The superficial plexus reduced its density ($p = 0.0073$). Changes in the other intervals were not statistically significant. An increase in density was recorded in the deep capillary plexus ($p < 0.0001$). A statistically significant change was recorded after 9 months ($p = 0.0002$). In the other intervals the changes were not statistically significant. Graph 3.

Development of surface of foveal avascular zone

The surface of the foveal avascular zone (FAZ) was evaluated on the Spectralis instrument with the aid of the

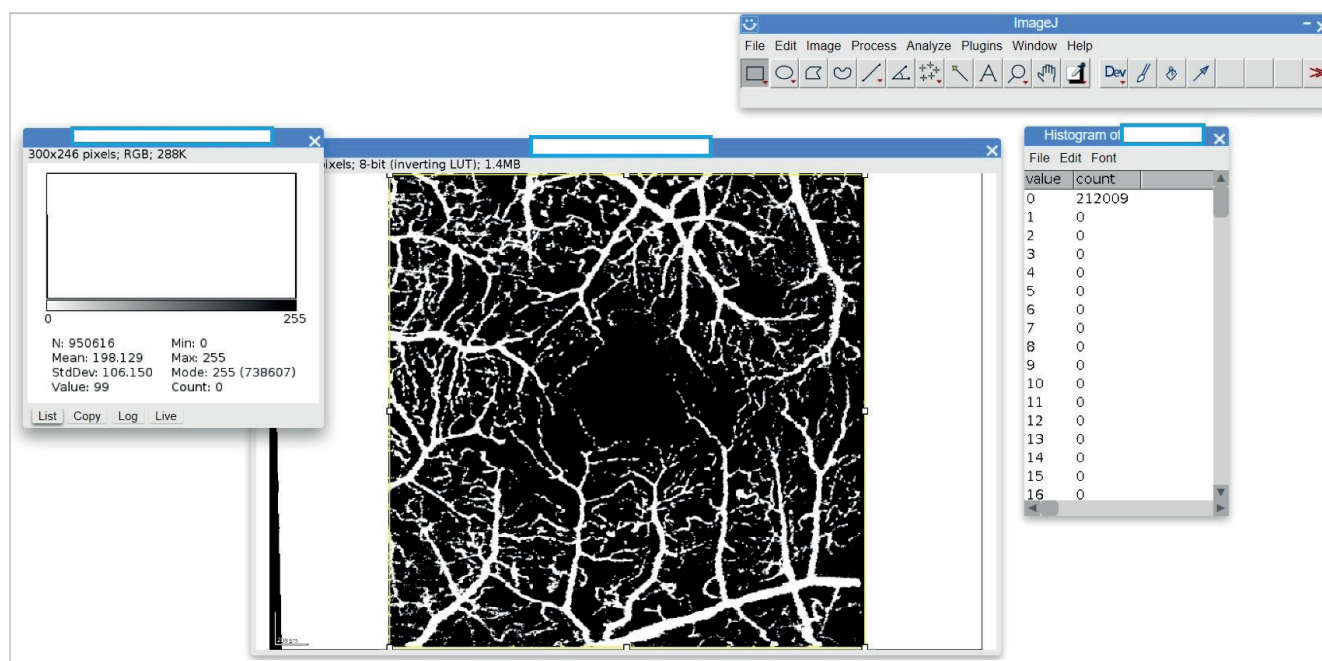
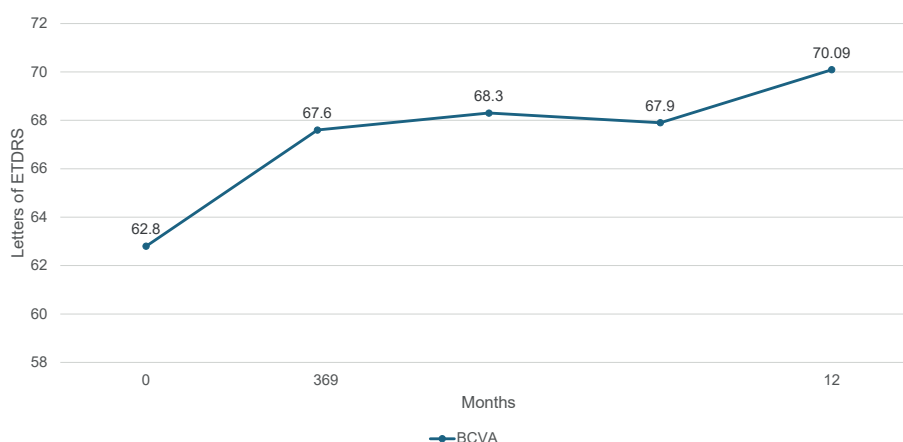


Figure 1. ImageJ Software and Its Applications



Graph 1. Development of the best corrected visual acuity ($p < 0.0001$)

ETDRS – Early treatment diabetic retinopathy study, BCVA – Best corrected visual acuity

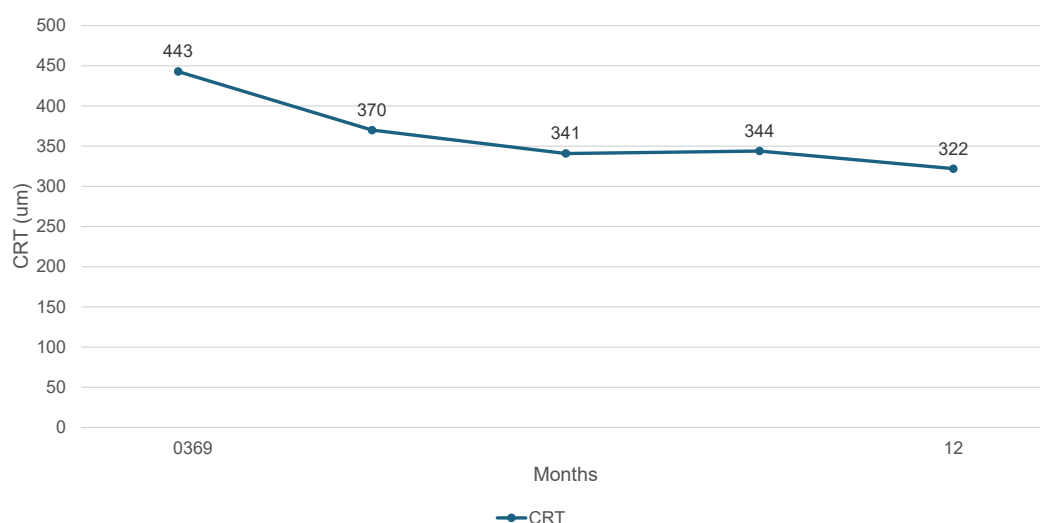
“draw region” function. In the evaluation we selected an image composed of the deep, intermediate and superficial capillary plexus in order to obtain maximum contrast in the imaging of the FAZ. Over the course of 12 months the surface of the FAZ was statistically significantly reduced from the original average value of $0.29 \pm 0.15 \text{ mm}^2$ to $0.24 \pm 0.07 \text{ mm}^2$ ($p = 0.040$). An enlargement of the surface of the FAZ was recorded in 8 eyes (26%). Graph 4.

DISCUSSION

Numerous studies dealing with morphological changes of capillaries in the macula within the framework of treatment of DME with the aid of anti-VEGF therapy have achieved varying results. The studies can be divided into

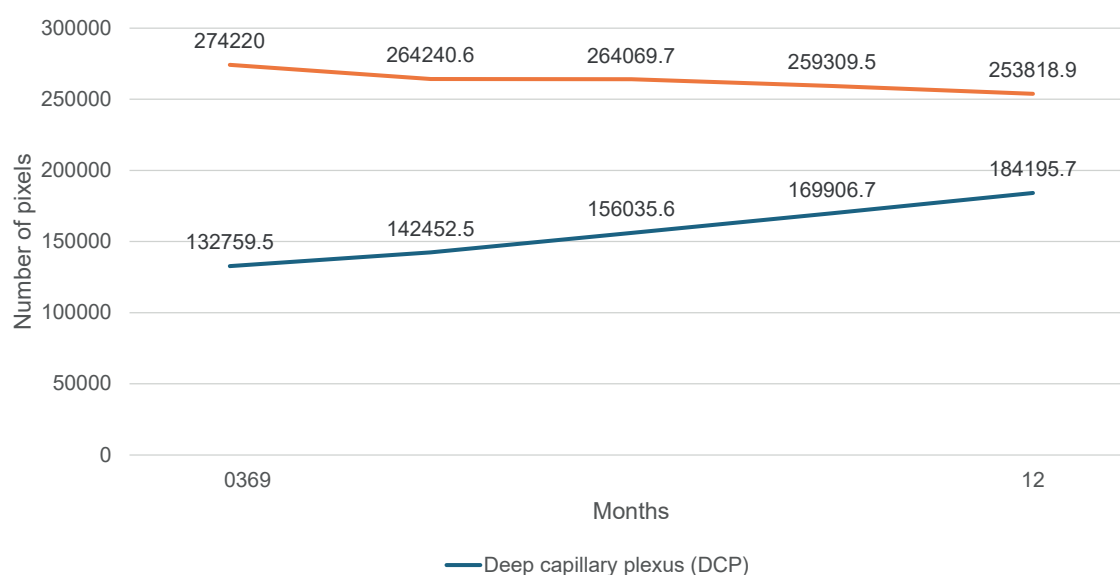
two groups; those that determined stability or improvement regarding the retinal capillary plexuses during the course of treatment, and studies which recorded a deterioration (reduction of density) of the capillary plexuses in the macula.

The study conducted by Hsieh YT et al. used the developed to order Matlab software (Mathworks, Natick, MA, USA) for processing and analysis of the OCTA image. Within the study patients with DME were administered 3 injections of ranibizumab at monthly intervals. Before and after application, five biomarkers of OCTA were evaluated, including the region of the FAZ, the circularity index of the FAZ, the average caliber of the capillaries, tortuosity of the capillaries and vascular density. The authors recorded a statistically significant



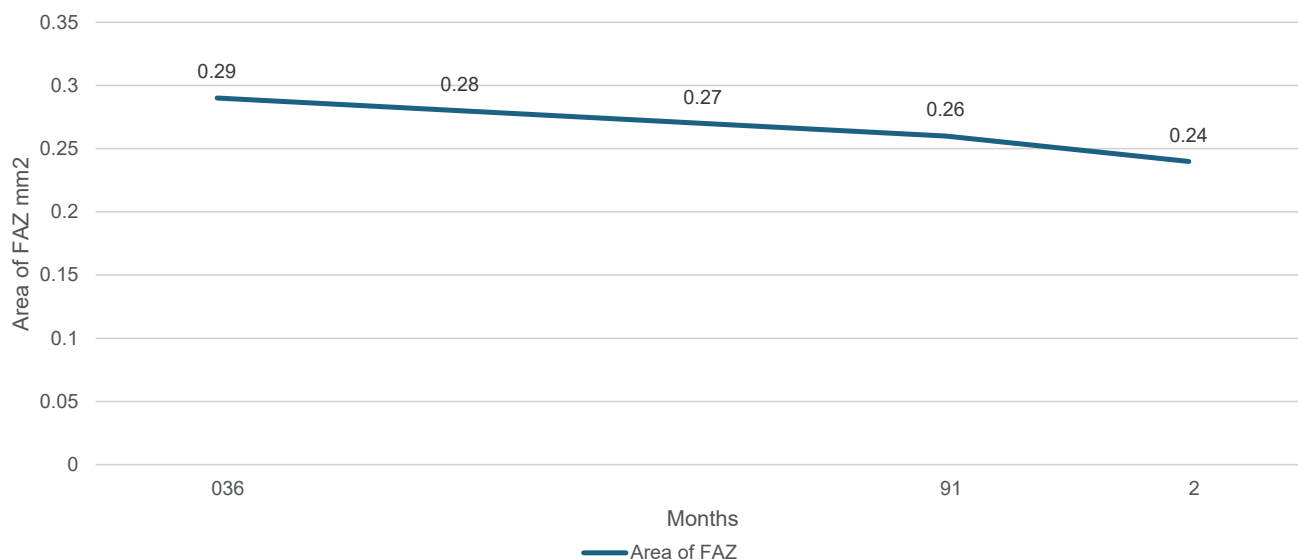
Graph 2. Development of central retinal thickness ($p < 0.0001$)

CRT – Central retinal thickness



Graph 3. Changes in retinal capillary plexus density (SCP: $p = 0.0073$ DCP: $p < 0.0001$)

DCP – Deep capillary plexus, SCP – Superficial capillary plexus



Graph 4. Development of foveolar avascular zone area ($p = 0.0406$)
FAZ – Foveolar avascular zone

improvement of the FAZ, average caliber of capillaries and inner and outer parafoveal vascular density of the SCP. However, these biomarkers did not improve to their normal values in comparison with a healthy control group. In comparison with this study we therefore attained similar results regarding improvement (reduction) of the surface of the FAZ. They differed in the result of SPC density, where in our study we recorded a decrease of vascular density in this plexus. The difference may have been caused by the shorter observation period, different software equipment and the use of only one active agent in this study. In our study there was also no control group of patients [9].

Golshani et al. prospectively assessed patients with DME who transferred from bevacizumab (95%) or ranibizumab (5 %) to aflibercept with the aid of OCT and OCTA (Optovue) (SWAP-TWO study). The patients received monthly injections of aflibercept until OCT demonstrated an absence of fluid, which was then followed by fixed dosing once every two months over a period of 12 months. After treatment there was no significant change in the region of the FAZ, but the vascular density of the SCP was significantly reduced by 5.2% ($p = 0.04$) and the DCP was significantly reduced by 6.3% ($p = 0.05$) within 12 months. This study did not have the same follow-up observation period as ours. In comparison we concur in the reduction of density in the SCP, while by contrast we differ in the development of the density of the DCP and the absence of change in the FAZ. The difference may be caused by the different main active agent (here bevacizumab) and the different instrument used to assess the OCTA scans [10].

In a prospective study of patients with persistent DME Statler et al. determined a significant decrease in the density in the superficial and deep capillary plexus following

intravitreal injections of aflibercept with a fixed interval over a period of 24 months. Better vision correlated with lesser loss of density of capillary perfusion. Only 16 patients complete the study. Before inclusion in the study, all the participants had a medical history of treatment with VEGF inhibitors. The OCTA Optovue instrument was used to assess the OCTA scans. This study concurs with ours in the reduction of density of the SCP, but there is a difference in the development in the DCP, where we recorded a statistically significant improvement in our results. The difference may again be caused by the different used anti-VEGF preparation (here only aflibercept), the different observation period and different hardware equipment [11].

OCTA is a noninvasive imaging modality which depends on a comparison of the decorrelation signals between repeated consecutive OCT B-scans obtained in quick succession in the same place on the retina. This enables detection of the motion contrast generated by the flow of red blood cells in the retinal capillaries, which leads to imaging of the perfused retinal capillaries and detection of the flow regions. OCTA therefore enables us to obtain reliable and reproducible measurements of vascular density, and thus enables objective assessment of the state of macular perfusion. On the basis of these properties, OCTA has considerable potential in evaluating diabetic retinopathy and is probably more suitable than traditional angiography in analysis of changes of vascular density following VEGF inhibition in diabetic patients. Nevertheless, OCTA remains a technology with several limitations. OCTA images may be significantly influenced by low signal strength, which leads to altered visualization of small capillaries. In addition to this, local loss of signals caused by localized opacity of the medium may be erroneously interpreted as regions with empty flow. Finally, it is necessary to take into consideration the fact

that OCTA imaging of capillaries at present is more influenced by artefacts and errors of interpretation in comparison with fluorescence angiography. These artefacts incorporate artefacts of movement and blinking (due to the extended scanning time), artefacts of shadows and artefacts of projection from the superficial layers. OCTA scans should therefore be interpreted with reference to these limitations in order to avoid reaching misleading or imprecise conclusions. This could explain why the results of studies conducted by different groups of examiners using OCTA may be different or conflicting. However, as OCTA technology improves and accelerates, many of these limitations and artefacts could be eliminated, which would lead to more reliable and more comparable results from studies with more solid conclusions.

Further reasons leading to the large variability in the results between studies are differences in the design of the study, differences in the characteristics of the patients and inclusion criteria, or in the methods of analysis of the image and quantification of vascular density. In our opinion, the relative cogency of each study and its overall significance depends on a number of factors, including the study design, number of included patients, length of treatment and number of administered injections, used therapeutic protocol and method of analysis of the image, which could not be assessed with the aid of the available scale because all the identified studies were non-comparative series of cases.

Some factors in connection with anti-VEGF treatment of DME can lead to an improvement of macular perfusion, whereas others can lead to a deterioration thereof. Even in a single patient it is evident that some regions of the macula are better perfused whereas other regions deteriorate after OCTA treatment, which indicates that several factors are at play in connection with VEGF inhibition, which influence macular perfusion. One of the factors that could lead to an improvement of retinal perfusion following treatment with anti-VEGF antibodies is reversal of leukostasis, which is induced in diabetic patients by excess secretion of VEGF and leads to increased occlusion of capillaries [12].

Another such factor is regeneration of the normal retinal architecture as a consequence of reduced intraretinal

edema [13] and inhibition of hypertrophy of the endothelial cells, which is induced by excessive local production of VEGF-A and leads to constriction and occlusion of the capillary lumen [14]. One of the factors that could explain the deterioration of retinal perfusion following VEGF inhibition is induction of vasoconstriction of the retinal vasculature, which was detected after injections of bevacizumab and ranibizumab for DME, probably as a consequence of inhibition of nitric oxide, which occurs upon VEGF inhibition and also leads to systemic hypertension in the case of systemic VEGF inhibition [15].

Loss of the pericytes which normally surround mature retinal capillaries and make them independent of VEGF for survival could be another cause of reduced density of capillaries following VEGF inhibition in diabetic patients [16]. It is known that loss of pericytes occurs in early DR and can cause the capillary endothelial cells to be sensitive to VEGF inhibition, which leads to a depletion of endothelial cells and subsequent loss of capillaries [17,18].

CONCLUSION

It ensues from the results of our study that treatment with anti-VEGF preparations (Lucentis, Eylea) as part of DME therapy statistically significantly improves the microvasculature of the macula, mainly in the deep capillary plexus of the retina, and thereby contributes to a reduction of the foveal avascular zone. We demonstrated a statistically significant improvement of BCVA and reduction of CRT in patients treated with ranibizumab and aflibercept.

In future, analysis of changes of vascular density following treatment of DME with anti-VEGF preparations with the aid of OCTA could be improved by the introduction of a uniform scanning protocol and analytical approach that uses similar criteria for inclusion of patients and elimination of potential sources of distortion. In the final result, this could produce definitive conclusions relating to the effect of these injections on the state of macular perfusion in diabetic patients. With future advances in OCTA technology, including increased scanning speed, development of better software for correction of image artefacts and broader scanning protocols, this evaluation shall be more reliable and more reproducible.

REFERENCES

1. Coscas F, Sellam A, Glacet-Bernard A, et al. Normative Data for Vascular Density in Superficial and Deep Capillary Plexuses of Healthy Adults Assessed by Optical Coherence Tomography Angiography. *Invest Ophthalmol Vis Sci.* 2016;57(9):OCT-211-OCT223
2. Braham IZ, Kaouel H, Boukari M, et al. Optical coherence tomography angiography analysis of microvascular abnormalities and vessel density in treatment-naïve eyes with diabetic macular edema. *BMC Ophthalmol.* 2022 Nov 3;22(1):418
3. Studnička J. Aflibercept v léčbě diabetického makulárního edému [Aflibercept in the Diabetic Macular Edema Treatment]. *Cesk Slov Oftalmol.* 2015;7:243-246. Czech.
4. Stino H, Birner K, Hinterhuber L, et al. Influence of OCT biomarkers on microperimetry intra- and interdevice repeatability in diabetic macular edema. *Sci Rep.* 2024 Oct 7;14(1):23342
5. Scholl S, Kirchhof J, Augustin AJ. Pathophysiology of macular edema. *Ophthalmologica* 2010;224:8-15.
6. Sosna T, Švancarová R, Netuková M, Studnička J. Současný pohled na diabetický makulární edém [Current Overview of Diabetic Macular Edema]. *Cesk Slov Oftalmol.* 2012;68:91-97. Czech.
7. Li YF, Ren Q, Sun CH, et al. Efficacy and mechanism of anti-vascular endothelial growth factor drugs for diabetic macular edema patients. *World J Diabetes.* 2022 Jul 15;13(7):532-542.
8. Lazár AS, Stanca HT, Tăbăcaru B, Danielelescu C, Munteanu M, Stanca S. Quantitative Parameters Relevant for Diabetic Macular Edema Evaluation by Optical Coherence Tomography Angiography. *Medicina (Kaunas).* 2023 Jun 10;59(6):1120.
9. Hsieh YT, Alam MN, Le D, et al. OCT Angiography Biomarkers for Predicting Visual Outcomes after Ranibizumab Treatment for Diabetic Macular Edema. *Ophthalmol Retina.* 2019 Oct;3(10):826-834.

10. Golshani C, Conti TF, Conti FF, et al. Diabetic Macular Edema Treated With Intravitreal Aflibercept Injection After Treatment With Other Anti-VEGF Agents (SWAP-TWO Study)-12-Month Analysis. *J Vitreoretin Dis.* 2020;4(5):364-371.
11. Statler B, Conti TF, Conti FF, et al. Twenty-Four-Month OCTA Assessment in Diabetic Patients Undergoing Fixed-Interval Intravitreal Aflibercept Therapy. *Ophthalmic Surg Lasers Imaging Retina.* 2020;51(8):448-455.
12. Tolentino MJ, Miller JW, Gragoudas ES, et al. Intravitreal injections of vascular endothelial growth factor produce retinal ischemia and microangiopathy in an adult primate. *Ophthalmology.* 1996;103(11):1820-1828.
13. Dastiridou A, Karathanou K, Riga P, et al. OCT Angiography Study of the Macula in Patients with Diabetic Macular Edema Treated with Intravitreal Aflibercept. *Ocul Immunol Inflamm.* 2021;29(5):926-931.
14. Hofman P, van Blijswijk BC, Gaillard PJ, Vrensen GF, Schlingemann RO. Endothelial cell hypertrophy induced by vascular endothelial growth factor in the retina: new insights into the pathogenesis of capillary nonperfusion. *Arch Ophthalmol.* 2001;119(6):861-866.
15. Kurt MM, Çekiç O, Akpolat Ç, Elçioglu M. Effects of intravitreal ranibizumab and bevacizumab on the retinal vessel size in diabetic macular edema. *Retina.* 2018;38(6):1120-1126.
16. Benjamin LE, Hemo I, Keshet E. A plasticity window for blood vessel remodelling is defined by pericyte coverage of the preformed endothelial network and is regulated by PDGF-B and VEGF. *Development.* 1998;125(9):1591-1598.
17. Stitt AW, Gardiner TA, Archer DB. Histological and ultrastructural investigation of retinal microaneurysm development in diabetic patients. *Br J Ophthalmol.* 1995;79(4):362-367.
18. Elnahry AG, Elnahry GA. Optical Coherence Tomography Angiography of Macular Perfusion Changes after Anti-VEGF Therapy for Diabetic Macular Edema: A Systematic Review. *J Diabetes Res.* 2021;2021:6634637.