

TOPIRAMATE-INDUCED BILATERAL ANGLE-CLOSURE GLAUCOMA. A CASE REPORT

Magera L., Baxant AD., Studený P.

Department of Ophthalmology, 3rd Faculty of Medicine, Charles University and University Hospital Kralovske Vinohrady, Prague, Czech Republic

The authors of the study declare that no conflict of interest exists in the compilation, theme and subsequent publication of this professional communication, and that it is not supported by any pharmaceutical company. The study has not been submitted to any other journal or printed elsewhere, with the exception of congress abstracts and recommended procedures.

Received: 23 October 2021

Accepted: 7 February 2022

Available on-line: 19 May 2022



MUDr. Lukáš Magera
Oftalmologická klinika FNKV
a 3. LFUK
Šrobárova 50
100 34 Praha 10
E-mail: lukasmagera@gmail.com

SUMMARY

Introduction: Topamax (topiramate) is a drug used in the treatment of epilepsy or migraine. Its use may rarely be associated with the occurrence of secondary angle-closure glaucoma due to supraciliary effusion. Although the ocular finding resembles primary angle-closure glaucoma, bilateral inflexion should always raise the suspicion that it is drug-induced glaucoma.

Case report: The authors present a case of a 51-year-old patient on Topamax therapy with sudden vertigo, headache and blurred vision. Ophthalmic examination revealed bilateral angle-closure glaucoma, which was initially treated in the classic manner by administration of local antiglaucoma drugs and pilocarpine, followed by administration of osmotically active substances and laser iridotomy. Only the subsequent discontinuation of Topamax and the use of local cycloplegics and corticosteroids led to the release of the anterior segment angle closure and normalization of intraocular pressure.

Conclusion: The indicating physician and ophthalmologist must be aware of the possible side effects of Topamax therapy, to determine the correct diagnosis and to administer treatment appropriately.

Key words: topiramate, topamax, epilepsy, migraine, angle-closure glaucoma, acute myopia

Čes. a slov. Oftal., 78, 2022, No. 3, p. 138–142

INTRODUCTION

Topiramate (Topiramatum, Janssen Pharmaceutica N.V., Belgium) is a broad-spectrum antiepileptic drug that is approved for preventing or reducing the frequency of epileptic seizures and for the prophylaxis of migraine. Certain ocular adverse clinical effects have also been noted, such as acute myopia and secondary bilateral angle-closure glaucoma. This adverse effect appears to be associated with supraciliary effusion and anterior displacement of the lens and iris associated with a narrowing of the angle between the iris and cornea. This condition usually arises within the first month of treatment with topiramate. Treatment consists of immediate discontinuation of topiramate and taking appropriate measures to reduce intraocular pressure [1].

CASE REPORT

A 51-year-old woman with a history of migraines without aura, treated with Topamax 50 mg/qd (for 2

weeks) and with sumatriptan 50 mg/qd, acutely attends the Neurological Clinic because of vertigo, headache and blurred vision that started in the morning. The CT angiography of the brain showed no pathological finding. According to the neurological and laboratory examination, the cause of the problems was not found. With the finding of anisocoria and bilateral areactive mydriasis, the patient was referred to the Eye Clinic. The patient's and family's ocular history was negative. She had just been wearing reading glasses since the age of 43.

The initial visual acuity (VA) of the right eye (OD) was 5/7.5 naturally and the VA of the left eye (OS) was 5/5 naturally, according to the refractometer, without any significant dioptric disorder. Intraocular pressure (IOP), measured by applanation Goldman tonometry (Zeiss AT 020, Carl Zeiss Meditec AG, Germany), was 62 mmHg OD and 74 mmHg OS. Ocular examination of both eyes showed normal conjunctiva, mild corneal edema, a shallow anterior chamber with the presence of cells and mydriatic pupil with poor light reaction. Gonioscopy and anterior-segment OCT (optical coherence tomography)

image (Spectralis, Heidelberg Engineering, Germany) (Figure 1) showed angle closure in both eyes, with circular choroidal detachment in the fundus periphery. Initially administered topical drugs were timololum 1x, dorzolamidum 1x, brimonidini tartras 1x and pilocarpinum hydrochloridum 1x, then acetazolamidum po and glycerol po, followed by mannitolum iv. YAG laser iridotomy (Ultra Q, Ellex, USA) was also performed acutely on both eyes. Despite this intensive therapy, the IOP dropped to only 60 mmHg OD and 58 mmHg OS and the patient was admitted to the Ophthalmic inpatient ward. On the second day, the IOP was 40 mmHg OD and 40 mmHg OS at maximal local antiglaucoma therapy. An anterior segment OCT image of both eyes showed the supraciliary

effusion (Figures 2 and 4). In addition, examination on the Scheimpflug camera (Pentacam HR, Oculus Optikgeräte GmbH, Germany) showed the forward movement of the iris and lens (Figure 6). Ultrasound B scan (Accutome, Keeler, USA) of both eyes showed a hyperechogenic line, corresponding to choroidal detachment (Figure 5). We proceeded to change the therapy. In addition to antiglaucoma drugs (timololum bid + dorzolamide bid), the cycloplegics homatropini hydrobromide tid and corticosteroids dexamethasone q3h were added to both eyes; diuretics (furosemidum po) were also added and Topamax was discontinued. This treatment modification led to the stabilization of the IOP to 17 mmHg OD and 14 mmHg OS, the VA OD and OS was 5/5 naturally. The con-

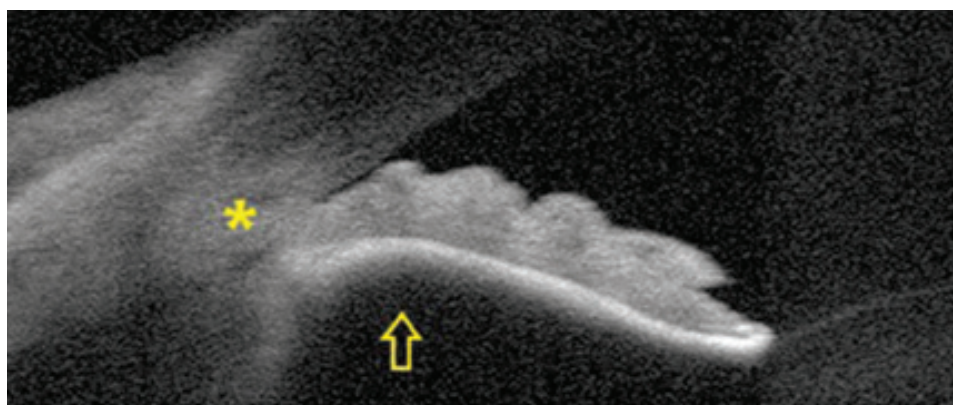


Figure 1. Initial anterior segment OCT image of the right eye, angle-closure (star), iris bulges forward (arrow), a relative pupillary block is also present

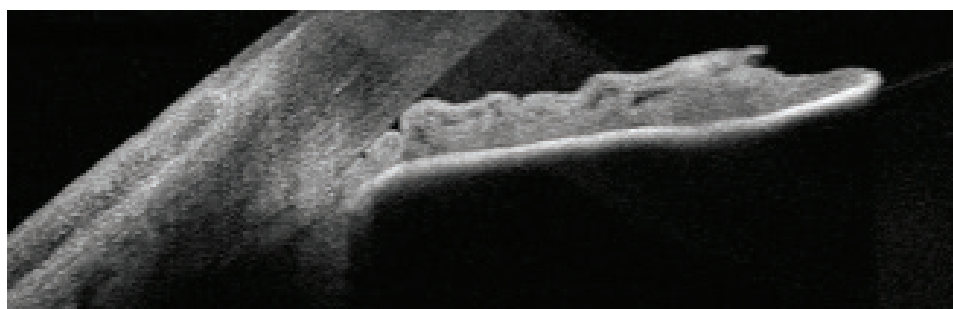


Figure 2. Anterior segment OCT image of the right eye after initial treatment, angle-closure is still present, the lens is dislocated anteriorly




Figure 3. Anterior segment OCT image of the right eye after the change in therapy, angle-closure begins to open (star)

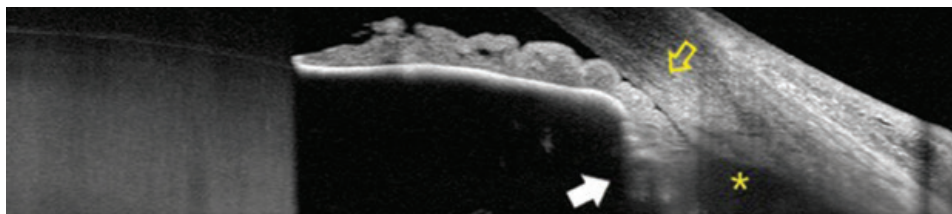


Figure 4. Anterior segment OCT image of the left eye after initial treatment, angle-closure (yellow arrow), forward rotation of the ciliary body (white arrow), supraciliary effusion (star)

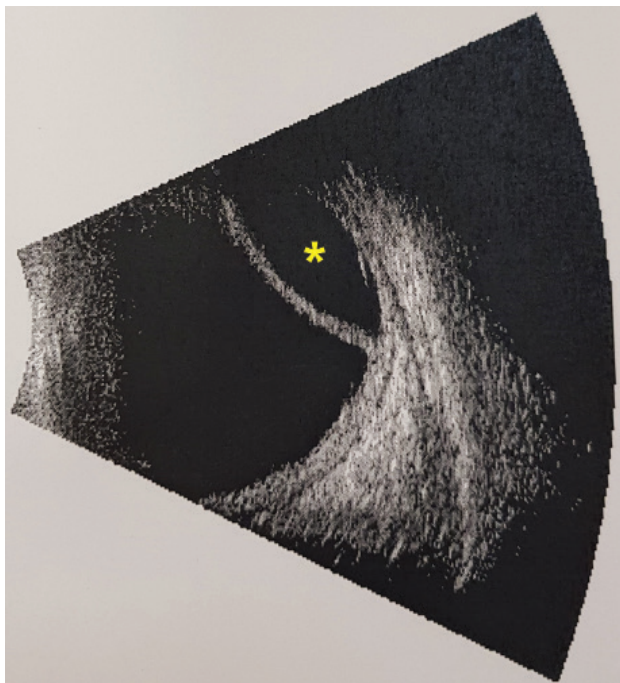

Figure 5. Ultrasound B scan of the left eye, choroidal detachment (star)

dition of the anterior segment was again documented on the OCT (Figure 3) and the patient was discharged to out-patient care. After 3 days, the IOP was 15 mmHg OD and 14 mmHg OS with the existing therapy. At the next check after 1 week, the IOP in both eyes was the same, the choroidal detachment was no longer evident on the fundus, according to examination on the Scheimpflug camera (Figure 7), the iris and lens were shifted posteriorly. We discontinued the cycloplegics, but gradually reduced the dose of local corticosteroids for another month, due to the prolonged presence of cells in the anterior chamber. The IOP remained well compensated and timolol bid and dorzolamide bid were left in both eyes, due to the noticeable loss in the nerve fiber layer documented on the OCT image. During the further observation, the perimetry was added (central threshold test 30–2 and 120, Humphrey HFA3, model 840, Carl Zeiss Meditec AG, Germany), always without pathological findings. In 1.5 years after the acute angle closure, the IOP decreased to 12 mmHg

OD and 14 mmHg OS. There was also a stabilization of the finding on the optic nerve OCT, so we discontinued the patient's therapy. The IOP remains below 15 mmHg OD and 15 mmHg OS, even without treatment, with no signs of progression on imaging tests.

DISCUSSION

Acute angle closure is an emergent ophthalmic condition that develops as a result of an obstructed out-flow of aqueous humor between the anterior and posterior chambers of the eye. The most common primary cause is a pupillary block in patients with pre-existing narrow angles [2]. The primary treatment option is medical therapy. The cholinergic agonist, pilocarpine, contracts the pupillary sphincter, pulling the peripheral iris away from the trabecular meshwork and therefore reopening the drainage angle. Topical steroids are also important to control the inflammation of the anterior segment and, finally, there are several agents used to reduce intraocular pressure. Laser peripheral iridotomy successfully eliminates the relative pupillary block component of the angle-closure process [3]. In this way, the acute condition can be resolved in some cases. In our case, similar treatment did not lead to a significant improvement. The patient's finding was atypical from the beginning – both eyes were affected and also circular choroidal detachment was reported. By performing anterior segment OCT, we gained a better overview of the anterior chamber, iridocorneal angle and ciliary body. If we encounter simultaneous bilateral acute angle-closure glaucoma, according to the published information there is a significant probability that this will not concern a case of primary acute angle-closure glaucoma, thus glaucoma incorporating pupillary block, but secondary angle-closure glaucoma caused by a different mechanism, in which the usual treatment of primary angle-closure glaucoma proves not only to be ineffective, but in many cases even worsens the condition [4]. Awareness should be raised to identify secondary causes of angle closure, including the use of commonly prescribed medications [2]. A number of local and systemic drugs can cause acute angle closure in susceptible individuals. These are alpha-agonists, anticholinergics and cholinergics, antidepressants and anxiolytics, sulfonamides, H1 and




Figure 6. Pentacam HR, anterior chamber, initial image, anterior displacement of the lens-iris diaphragm (arrows) causing the anterior chamber shallowing




Figure 7. Pentacam HR, anterior chamber, after successful therapy, lens-iris diaphragm moved backward and caused the anterior chamber deepening

H2 histamine receptor antagonists and other substances. The mechanism of action tends to be different. Acute angle closure due to pupillary block is treatable by laser peripheral iridotomy. However, in the case of suprachoroidal effusion or vitreous hemorrhage, which causes anterior displacement of the lens and iris and concomitant shallowing of the anterior chamber [5], laser iridotomy is not effective [5,6]. There were reports of acute angle closure (AAC) associated with topiramate use, which may involve ciliochoroidal effusion, forward displacement of the iris-lens diaphragm. However, to date, there is no evidence that the short-term use of topiramate does induce asymptomatic angle narrowing [7]. Similarly, there is no evidence of a higher incidence of AAC in patients taking topiramate with hypermetropia or preexisting narrow angle [6]. The risk of angle-closure glaucoma in patients younger than 50 years was more than 5 times higher in patients taking topiramate [8]. Topiramate is used to prevent migraine headache, that is more prevalent in women than men [9] and is also used to prevent seizures in patients with epilepsy, which affects more men than women [10]. Therefore, the risk of developing AAC for each sex results from a neurological diagnosis. There is a clinical impression that there are more adverse effects reported by migraineurs than epileptics and ocular adverse effects are not dose-dependent [11]. Most cases of AAC occurred in the first 2 weeks of treatment with topiramate, but the onset ranged from 1 to 49 days [6]. However, a later occurrence after 262 days of treatment is also reported [12]. Topiramate-related AAC most commonly occurs in both eyes at once, often with acute myopia and suprachoroidal

effusion [6]. If the cause of AAC is determined correctly, complete discontinuation of topiramate will resolve the issue. To reduce the intraocular pressure, it is advisable to use only some of the topical antiglaucomatics. The administration of prostaglandins and pilocarpine is controversial, as topiramate-related AAC may also have an inflammatory component [13], the presence of uveitis [14] and vitritis has been reported [15]. Pilocarpine is also contraindicated, due to ciliary muscle spasm effect and worsening of the choroidal detachment. On the contrary, it is appropriate to administer local cycloplegics [4], which relax the ciliary muscles, strengthen the zonular fibers, and this leads to posterior displacement of the lens. Equally important is the administration of topical corticosteroids [4], because suprachoroidal effusion probably occurs on an allergic and inflammatory basis. Of the systemic agents, mannitol can be used to reduce the intraocular pressure [16]. Conversely, acetazolamide should be avoided, because of a cross-sensitivity reaction, it is also known to cause ciliochoroidal effusion, angle-closure glaucoma and uveitis [17].

CONCLUSION

One of the rare topiramate adverse effects is bilateral acute angle closure due to supraciliary effusion. Women and younger patients are more often affected. The most common symptom is blurred vision, eye and head pain. Physicians prescribing topiramate must be well aware of this adverse effect and inform their patients in advance. The ophthalmologist also has a difficult task to correctly distinguish

the condition from primary angle-closure glaucoma and then to treat the patient correctly. Atypical findings, such as bilateral occurrence, the presence of acute myopia, the finding of supraciliary effusion on anterior segment OCT image, and a thorough phar-

macological history, may be a guide. Treatment consists of discontinuation of topiramate, topical use of cycloplegics and corticosteroids, or the use of topical beta-blockers and carbonic anhydrase inhibitors to reduce the intraocular pressure.

REFERENCES

1. Shank RP, Maryanoff BE. Molecular pharmacodynamics, clinical therapeutics, and pharmacokinetics of topiramate. *CNS Neurosci Ther.* 2008;14(2):120-142.
2. Flores-Sánchez BC, Tatham AJ. Acute angle closure glaucoma. *Br J Hosp Med (Lond).* 2019;80(12):174-179.
3. Sun X, Dai Y, Chen Y, et al. Primary angle closure glaucoma: What we know and what we don't know. *Prog Retin Eye Res.* 2017;57:26-45.
4. Štěpánková J, Kinštová L, Gažová I, et al. Simultaneous bilateral acute angle-closure glaucoma in Miller Fisher syndrome. *Cesk Slov Oftalmol.* 2019;75(4):210-218.
5. Lachkar Y, Bouassida W. Drug-induced acute angle closure glaucoma. *Curr Opin Ophthalmol.* 2007;18(2):129-133.
6. Fraunfelder FW, Fraunfelder FT, Keates EU. Topiramate-associated acute, bilateral, secondary angle-closure glaucoma. *Ophthalmology.* 2004;111(1):109-111.
7. Leung DY, Leung H, Baig N, et al. Topiramate and asymptomatic ocular angle narrowing: a prospective pilot study. *Eye (Lond).* 2009;23(11):2079-2081.
8. Symes RJ, Etminan M, Mikelberg FS. Risk of angle-closure glaucoma with bupropion and topiramate. *JAMA Ophthalmol.* 2015;133(10):1187-1189.
9. Vetvik KG, MacGregor EA. Sex differences in the epidemiology, clinical features, and pathophysiology of migraine. *Lancet Neurol.* 2017;16(1):76-87.
10. Reddy DS. The neuroendocrine basis of sex differences in epilepsy. *Pharmacol Biochem Behav.* 2017;152:97-104.
11. Gopalakrishna M, Odayappan A, Srinivasan K, Rengaraj V. A case series of topiramate-induced angle closure crisis - an ophthalmic emergency. *Cephalalgia.* 2020;40(12):1389-1393.
12. Czyz CN, Clark CM, Justice JD, Pokabla MJ, Weber PA. Delayed topiramate-induced bilateral angle-closure glaucoma. *J Glaucoma.* 2014;23(8):577-578.
13. Lan YW, Hsieh JW. Bilateral acute angle closure glaucoma and myopic shift by topiramate-induced ciliochoroidal effusion: case report and literature review. *Int Ophthalmol.* 2018;38(6):2639-2648.
14. Acharya N, Nithyanandam S, Kamat S. Topiramate-associated bilateral anterior uveitis and angle closure glaucoma. *Indian J Ophthalmol.* 2010;58(6):557-559.
15. Viet Tran H, Ravinet E, Schnyder C, Reichhart M, Guex-Crosier Y. Blood-brain barrier disruption associated with topiramate-induced angle-closure glaucoma of acute onset. *Klin Monbl Augenheilkd.* 2006;223(5):425-427.
16. van Issum C, Mavranakas N, Schutz JS, Shaarawy T. Topiramate-induced acute bilateral angle closure and myopia: pathophysiology and treatment controversies. *Eur J Ophthalmol.* 2011;21(4):404-409.
17. Kamal S, Yadava U, Kumar S, Goel R. Topiramate-induced angle-closure glaucoma: cross-sensitivity with other sulphonamide derivatives causing anterior uveitis. *Int Ophthalmol.* 2014;34(2):345-349.